Diagn Interv Radiol 2020; 26:315–322
© Turkish Society of Radiology 2020

CHEST IMAGING
ORIGINAL ARTICLE

COVID-19 S: A new proposal for diagnosis and structured reporting of COVID-19 on computed tomography imaging

Naciye Sinem Gezer
Begüm Ergan
Mustafa Mahmut Barış
Özgür Appak
Ayça Arzu Sayıner
Pınar Balcı
Ziya Kuruüzüm
Sema Alp Çavuş
Oğuz Kılınç

PURPOSE
Because of the widespread use of computed tomography (CT) in the diagnosis of COVID-19, indeterminate presentations such as single, few or unilateral lesions amount to a considerable number. We aimed to develop a new classification and structured reporting system on CT imaging (COVID-19 S) that would facilitate the diagnosis of COVID-19 in the most accurate way.

METHODS
Our retrospective cohort included 803 patients with a chest CT scan upon suspicion of COVID-19. The patients' history, physical examination, CT findings, RT-PCR, and other laboratory test results were reviewed, and a final diagnosis was made as COVID-19 or non-COVID-19. Chest CT scans were classified according to the COVID-19 S CT diagnosis criteria. Cohen's kappa analysis was used.

RESULTS
Final clinical diagnosis was COVID-19 in 98 patients (12%). According to the COVID-19 S CT diagnosis criteria, the number of patients in the normal, compatible with COVID-19, indeterminate and alternative diagnosis groups were 581 (72.3%), 97 (12.1%), 16 (2.0%) and 109 (13.6%). When the indeterminate group was combined with the group compatible with COVID-19, the sensitivity and specificity of COVID-19 S were 99.0% and 87.1%, with 85.8% positive predictive value (PPV) and 99.1% negative predictive value (NPV). When the indeterminate group was combined with the alternative diagnosis group, the sensitivity and specificity of COVID-19 S were 93.9% and 96.0%, with 94.8% PPV and 95.2% NPV.

CONCLUSION
COVID-19 S CT classification system may meet the needs of radiologists in distinguishing COVID-19 from pneumonia of other etiologies and help optimize patient management and disease control in this pandemic by the use of structured reporting.

Coronavirus disease 2019 (COVID-19) is a newly emerging respiratory disease originating from the severe acute respiratory syndrome coronavirus 2 (SARS-CoV-2), which was first identified in 2019 in Wuhan, the capital of China's Hubei province (1, 2). Although control precautions have been applied to prevent further spread, the number of patients has been rapidly increasing worldwide (3, 4). The World Health Organization (WHO) declared the outbreak to be a public health emergency of international concern and recognized it as a pandemic on 11 March 2020 (5). Since 31 December 2019 and as of 26 May 2020, 5 459 528 cases of COVID-19 (in accordance with the applied case definitions and testing strategies in the affected countries) have been reported, including 345 994 deaths (6). Evidently, there is need for better diagnosis and treatment of COVID-19 to overcome this pandemic, since the number of infected patients continues to increase rapidly (4).

The current diagnostic test for COVID-19 is real-time fluorescence reverse transcription-polymerase chain reaction (RT-PCR) of samples collected via nasopharyngeal swabs (7). The RT-PCR test is highly specific but has a low sensitivity (37%–71%), meaning that the test can be negative even if the patient is infected (8–11). False negative RT-PCR tests have been reported in patients with computed tomography (CT) findings of COVID-19 who eventually tested positive with serial sampling (12). Moreover, there is a waiting period of up to 2 days for

From the Departments of Radiology (N.S.G. ✉ *drsinemgezer@gmail.com*, M.M.B., P.B.), Pulmonary and Critical Care (B.E.), Medical Microbiology (Ö.A., A.A.S.), Infectious Disease and Clinical Microbiology (Z.K., S.A.Ç.), and Department of Pulmonology and Critical Care (O.K.), Faculty of Medicine, Dokuz Eylül University, Izmir, Turkey.

Received 13 May 2020; revision requested 25 May 2020; last revision received 27 May 2020; accepted 28 May 2020.

Published online 17 June 2020.

DOI 10.5152/dir.2020.20351

You may cite this article as: Gezer NS, Ergan B, Barış MM, et al. COVID-19 S: A new proposal for diagnosis and structured reporting of COVID-19 on computed tomography imaging. Diagn Interv Radiol 2020; 26:315–322.

the test result to be available. For this reason, in daily practice, physicians appear to be applying chest CTs for prompt diagnosis and to decide whether to perform testing in cases where RT-PCR testing is difficult to provide (13). Thus, chest CT plays an important role in the diagnosis and management of COVID-19 although it is not recommended to be used as a screening tool or as a first-line test to diagnose COVID-19.

British Society of Thoracic Imaging, Fleischner Society and American College of Radiology recommend CT only for the diagnosis of seriously ill patients with uncertain or normal chest X-ray findings and if any complication is suspected during the follow-up (14–16). Additionally, chest CT is reported to contribute to the early detection of lung abnormality, suggest disease severity and identify possible co-infections in hospitalized patients (14–16). Since CT has such an important place in the diagnosis and management of COVID-19, workload in the radiology departments during the pandemic has significantly increased (13). Also, the workload of physicians working with this group of patients has significantly increased. It is suggested that using structured reporting templates may be an effective way of reducing workload and combating the pandemic (16). It would facilitate accurate radiologic diagnosis and reduce radiologists' variability in the reporting of chest CT as well as variability in the interpretation of CT reports by clinicians (16). This would prevent the waste of precious time and misunderstandings caused by uncertainty or variation in the CT reports. For this reason, various viable diagnostic criteria and structured reports for COVID-19 have emerged in the literature, typically classifying CT findings as classic COVID-19, probable COVID-19, indeterminate and non-COVID-19 (14, 16). Because of the widespread use of CT imaging, indeterminate presentations of the disease, such as single, few or unilateral lesions, have reached a considerable number. This uncertainty causes difficulties in patient management and management of the pandemic. We suggest that a more accomplished classification system be developed, given that experiences of COVID-19 and its imaging findings are rapidly increasing.

The purpose of this study was to develop a new classification and structured reporting system on CT imaging that would facilitate the diagnosis of COVID-19 in the most accurate way, according to the data obtained from the current literature.

Main points

- When the indeterminate group was combined with the group compatible with COVID-19, the sensitivity and specificity of the COVID-19 S CT classification were 99.0% and 87.1%, respectively.
- When the indeterminate group was combined with the alternative diagnosis group, the sensitivity and specificity of COVID-19 S were 93.9% and 96.0%, respectively.
- The negative predictive value (99.1%) was higher when the indeterminate group was combined with the group compatible with COVID-19, while the positive predictive value (94.8%) was higher when the indeterminate group was combined with the alternative diagnosis group.

Methods

We performed a retrospective, single-center study. This study was approved by the ethics committee of our institutional board (2020/09-39/11.05.2020) and the Republic of Turkey Ministry of Health, COVID-19 Scientific Research Committee. The requirement for informed consent was waived since the study had no risk and would not adversely affect the subjects' rights or welfare. Patient selection was performed consecutively.

Patient selection

The present study included 803 patients: 416 men (51.8%) and 387 women (48.2%); age range, 19–94 years; mean age ± standard deviation, 45.43±17.6 years. Patients included in the study had been admitted to the pandemic clinic of our hospital between March 21, 2020, and April 3, 2020, and had had a chest CT scan upon suspicion of COVID-19-associated pneumonia because of high fever (>38°C) and respiratory system symptoms such as dyspnea and cough. Patients under the age of 18 were not included in the study. The patients' history, physical examination findings, RT-PCR, white blood cell count and other laboratory test results, such as serum procalcitonin, C-reactive protein and D-dimer, were extracted from the patients' electronic medical records in the hospital information system. Then, the final diagnosis was made by consensus of two physicians as COVID-19 or non-COVID-19 based on the medical records and CT scans. For patients with multiple RT-PCR results, a positive result was recorded as confirmation of diagnosis. No exclusion criteria were applied in this study.

Chest CT image acquisition

A 64-channel multidetector CT scanner (Brilliance, Philips Medical Systems) reserved for COVID-19 suspected patients was used for imaging. To minimize cross-contamination, CT scans were performed by two radiology technicians, one managing the CT scanner and the other in contact with the patient. Suspected patients wore medical mask, while radiology technicians donned medical mask, gown, gloves, and face shield. CT room was decontaminated by thorough cleaning of surfaces with sodium hypochlorite solution, allowing at least 10 min of contact time and maintaining proper ventilation and airflow.

CT examinations were performed with the patient in the supine position during end-inspiration without intravenous contrast medium. CT imaging protocol was as follows: 120 kVp, 80 mA, slice thickness 1 mm, and high-spatial-frequency reconstruction algorithm (bone algorithm). Axial scans were reconstructed with a slice thickness of 1.5 mm and reconstruction increment of 0.75 mm to obtain coronal plane images. Lung window setting was with a window level of -600 Hounsfield units and window width of 1500 Hounsfield units.

Interpretation of chest CT scan

The typical chest CT findings seen in COVID-19 pneumonia, change of these findings over time in the course of the disease and atypical findings are described in the current literature (16–20). Also, findings that are incompatible with COVID-19 pneumonia have been clearly defined (16, 17, 21). In this study, initial chest CT images of all patients in axial and coronal reformated slices were evaluated by two experienced (14 years each) radiologists (R1 and R2), board-certificated in radiology, in consensus. For patients with multiple CT scans, only the first one with pathologic findings was included in the study.

CT scans were reviewed for elementary COVID-19 lesions and radiologically classified according to the following criteria, which were created in the light of the current literature and our experiences: 1) normal, 2) compatible with COVID-19, 3) indeterminate and 4) alternative diagnosis. Figs.1–6 and Table 1 give a detailed description of the CT characteristics of an elementary COVID-19 lesion and explanation of the structured reporting system, COVID-19 S, used for CT classifica-

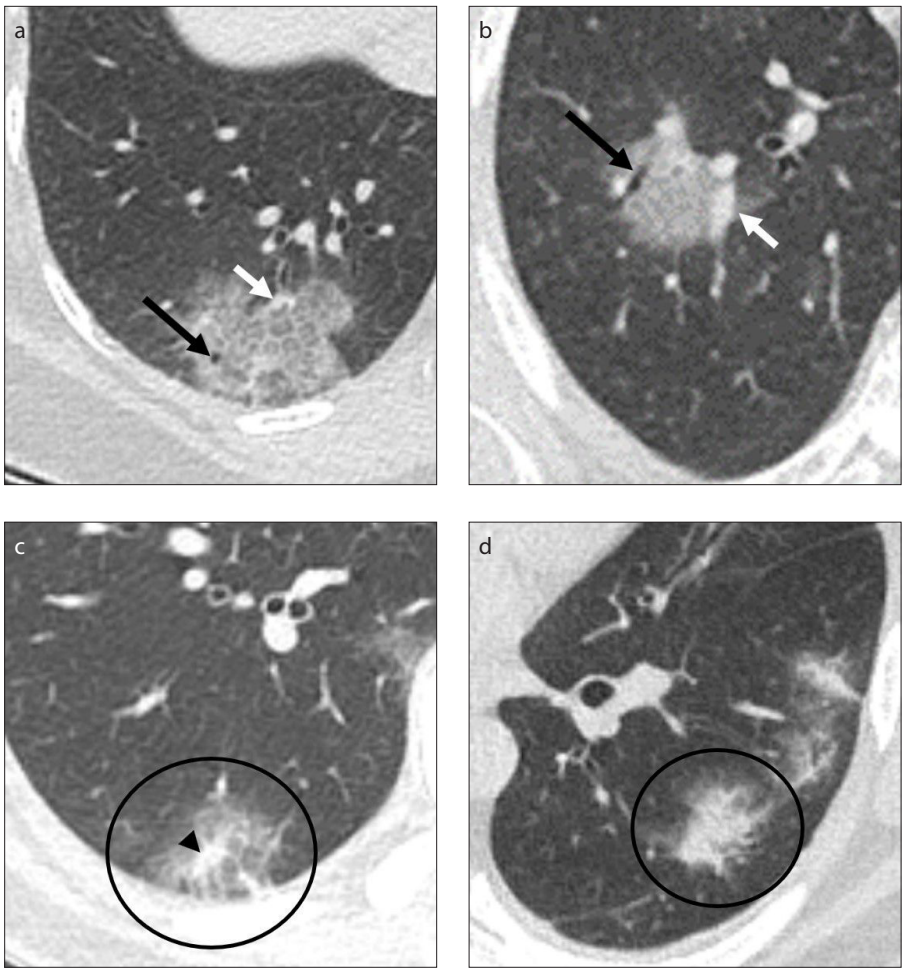

Figure 1. a–d. Axial images of unenhanced chest CT show common characteristics of elementary COVID-19 lesion. In image **(a)**, peripheral ground glass opacity (GGO) located at posterior basal segment of right lower lobe with lobulated contours, internal reticulations, bronchial dilatation *(black arrow)* and vascular enlargement *(white arrow)* demonstrates crazy paving pattern. Image **(b)** shows a bronchocentric GGO with rounded contours, air bronchogram *(black arrow)* and vascular enlargement *(white arrow)*. Image **(c)** shows a peripheral rounded GGO with internal reticulations and central consolidation *(arrowhead)*. Image **(d)** shows peripheral rounded consolidation with a peripheral GGO demonstrating the halo sign.

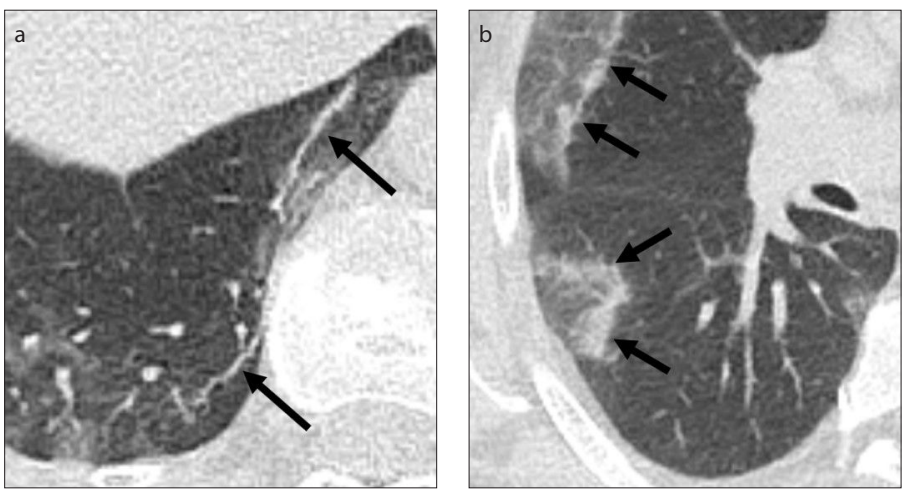

Figure 2. a, b. Axial images of unenhanced chest CT show less common characteristics of elementary COVID-19 lesion. Image **(a)** shows peripheral patchy GGOs with curvilinear irregular thick lines *(arrows)*. Image **(b)** shows GGOs with peripheral rim consolidation demonstrating the reverse halo sign.

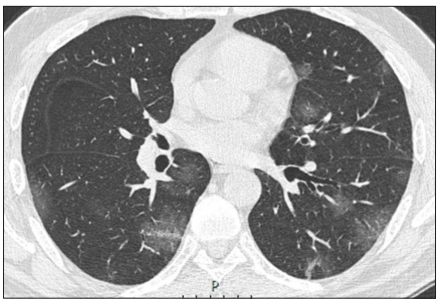

Figure 3. Axial image of unenhanced chest CT obtained five days after the onset of symptoms shows bilateral peripheral and bronchocentric discrete GGOs with round contours and internal reticulations which are predominantly located posteriorly.

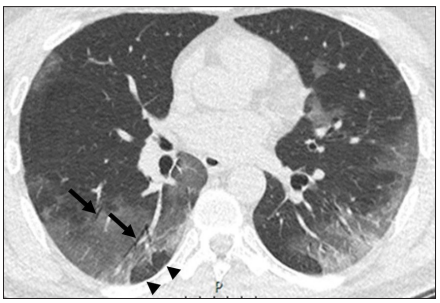

Figure 4. Axial image of unenhanced chest CT of the same patient in Fig. 3 obtained four days after the initial CT shows bilateral coalescent GGOs with geographic contours, perilobular sparing *(arrowheads)* and air bronchogram *(arrows)*.

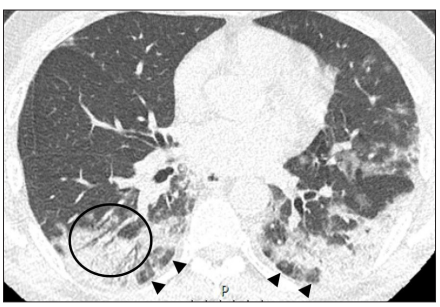

Figure 5. Axial image of unenhanced chest CT of the same patient in Figs. 3 and 4 obtained eleven days after the initial CT shows bilateral posteriorly located geographic infiltration predominantly in the form of consolidation with perilobular sparing *(arrowheads)* and air bronchogram *(circle)*.

tion in this study. Ground-glass opacification (GGO) was defined as hazy, increased lung attenuation with preservation of the bronchial and vascular margins, and consolidation was defined as opacification with obscuration of the margins of vessels and airway walls (22).

The CT scans were also evaluated for the following characteristics of the lesions: 1) location of the infiltration: the right up-

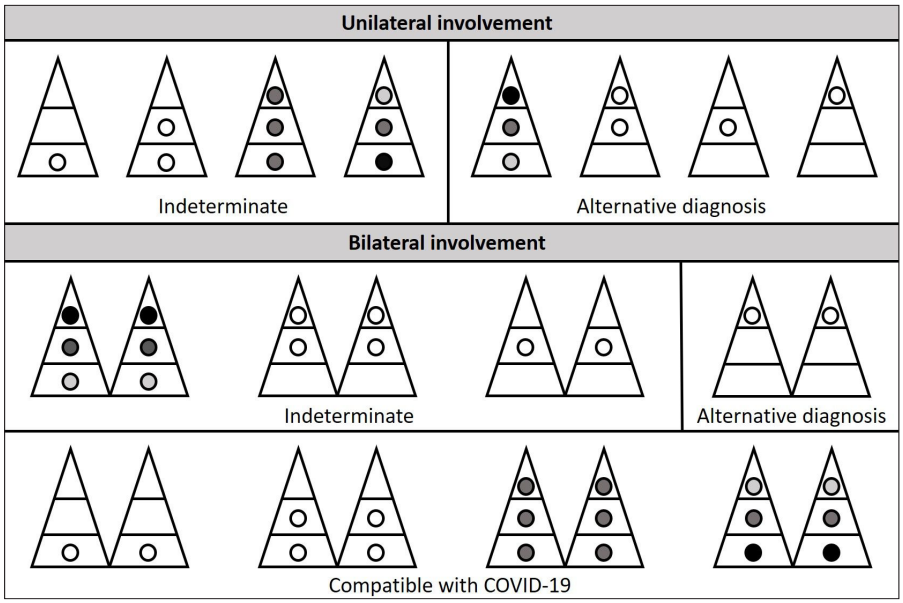

Figure 6. Diagram of COVID-19 S CT classification system. Divisions in triangles represent zones of the lung. Empty circles indicate that predominance of the lesions is insignificant. Darkness of the circles indicate dominancy of the lesions.

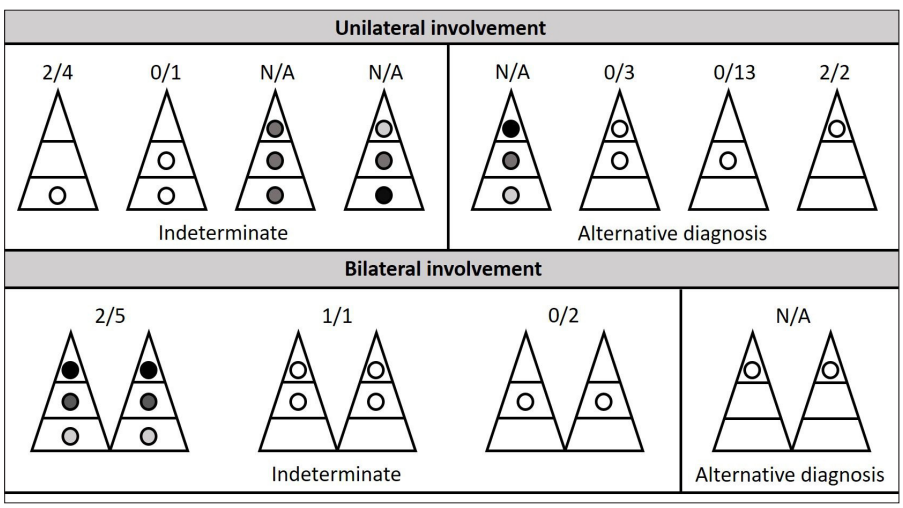

Figure 7. Distribution of the patients in indeterminate group (n=16) and the patients in alternative diagnosis group with non-COVID elementary lesions (n=15) and final clinical diagnosis of those patients are shown on diagram of COVID-19 S CT classification system. Ratios indicate the number of patients with final clinical diagnosis of COVID-19 / total number of patients presenting the pattern. Divisions in triangles represent zones of the lung. Empty circles indicate that predominance of the lesions is insignificant. Darkness of the circles indicate dominancy of the lesions. N/A, not available.

per, middle, right lower, left upper or left lower lobes, or any combination of these; 2) dominant location of the infiltration: the upper, middle or lower zones, or any combination of these; and 3) distribution of the infiltration: the central 2/3, peripheral 1/2 or bronchocentric (along the bronchovascular bundles) or any combination of these.

Statistical analysis

The statistical analysis was performed using the SPSS 23.0 for Windows software (IBM Corp.). Continuous data were expressed as mean ± standard deviation, while categorical data were presented as number of patients and percentage. Cohen's kappa analysis was done to compare the concordance of the CT diagnosis with the final clinical diagnosis. We calculated the sensitivity, specificity, positive predictive value (PPV) and negative predictive value (NPV) of the COVID-19 S CT classification, to offer a better management strategy for the disease. A P value < 0.05 indicated statistical significance.

Results

In our retrospective cohort of 803 patients, final clinical diagnosis was COVID-19 in 98 patients. Among all patients, RT-PCR results were available for 347, and 104 of them indicated COVID-19. Among 222 patients with pulmonary infiltrates on chest CT, 77 had positive RT-PCR result and 68 had negative RT-PCR result; RT-PCR results were not available for 77 patients. The number of patients with a final clinical diagnosis of COVID-19 were 75 and 16 in RT-PCR positive and RT-PCR negative groups respectively. Among 77 patients whose RT-PCR results were not available, 7 had a final clinical diagnosis of COVID-19 (Fig. 7).

According to the COVID-19 S CT diagnosis criteria, CT findings were normal in 581 (72.3%), compatible with COVID-19 in 97 (12.1%), indeterminate in 16 (2.0%), and alternative diagnosis in 109 (13.6%). The distribution of the patients in the indeterminate group (n=16) and those in the alternative diagnosis group with non-COVID-19 elementary lesions (15), and the clinical diagnoses of these are shown in Fig. 8. Among 581 patients with a normal chest CT, 26 (4.5%) had a positive RT-PCR test result and 175 (30.1%) had a negative one. The average number of days between CT and RT-PCR test was 2.13±3.2 days.

CT scans of 98 patients whose final clinical diagnosis was COVID-19 showed that the disease affected all five lobes in 63 patients (64.3%) ; both upper and lower lobes in seven patients (7.1%); both lower and middle lobes in five patients (5.1%); both lower lobes in three patients (3.1%); left upper and both lower lobes in three patients (3.1%); right upper, middle and both lower lobes in five patients (5.1%); middle and left lower lobes in two patients (2.0%); only right or left lower lobe in two patients (2.0%); left lower and both upper lobes in two patients (2.0%); left upper and right lower lobes in one patient (1.0%); right upper and both lower lobes in one patient (1.0%); left upper, middle and left lower lobes in one patient (1.0%); both upper, middle and right lower lobes in one patient (1.0%); left upper, middle and both lower lobes in one patient (1.0%); and left upper and right lower lobes in one patient (1.0%). The CT scan of a patient who was clinically diagnosed as COVID-19, but classified as alternative diagnosis upon imaging findings showed segmental consolidation and accompanying atelectasis in the right lower

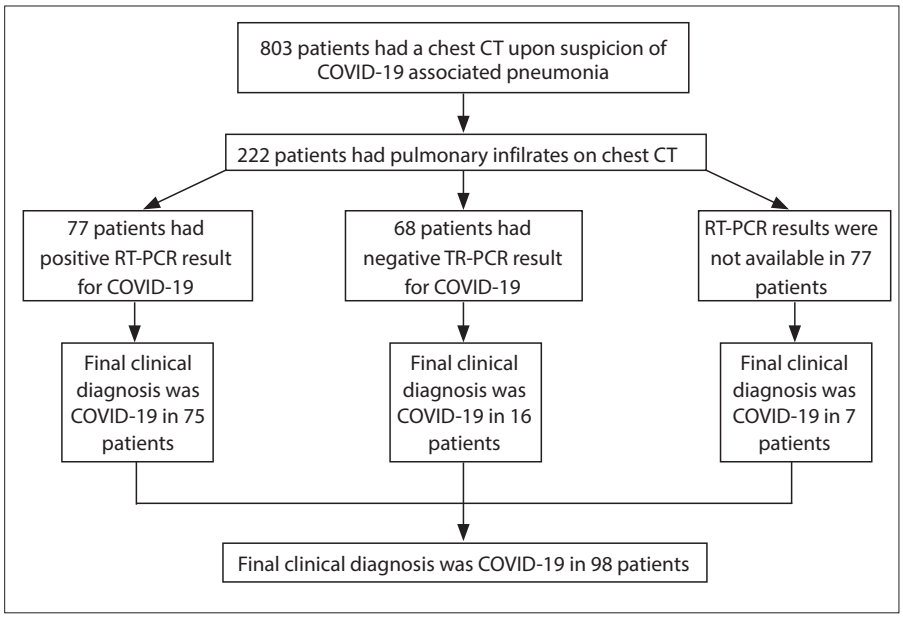

Figure 8. Flowchart of the patients with a chest CT upon suspicion of COVID-19 associated pneumonia. CT, computed tomography; COVID-19, coronavirus disease 2019; RT-PCR, real-time fluorescence reverse transcription-polymerase chain reaction.

lobe, acinar nodular infiltrations in the superior segment of the left lower lobe and peripheric patchy GGO in both upper lobes. Other than this patient, the predominant distribution of the lesions were the middle and lower zones in 44 patients (44.9%), lower zones in 29 patients (29.6%), and upper and middle zones in three patients (3.1%), while 21 (21.4%) of the CT scans demonstrated an equal distribution in upper, middle and lower zones. The locations of lesions were peripheral and bronchocentric in 65 (66.3%) patients, peripheral in 32 patients (32.7%) and central and bronchocentric in one patient (1.0%).

Among 222 chest CT scans with pulmonary infiltration, 97 (43.7%) were classified as compatible with COVID-19 upon chest CT findings under COVID-19 S and 92 (41.5%) of them had a final diagnosis of COVID-19. Out of 109 (49.1%) patients who were classified as alternative diagnosis under COVID-19 S, only one (0.5%) was COVID-19. Out of 16 patients (7.2%) who were classified as indeterminate, five (2.2%) were COVID-19 and 11 (5.0%) were non-COVID-19. The final clinical diagnoses of each group are shown in Table 2.

Among the alternative diagnosis group, 43 patients (39.4%) were diagnosed with bronchopneumonia, 20 (18.3%) with bronchiolitis, 18 (16.5%) with non-COVID-19 elementary lesions, 10 (9.2%) with pulmonary edema, nine (8.3%) with lobar pneumonia, four (3.7%) with bronchiolitis and bronchopneumonia, two (1.8%) with interstitial pneumonia, two (1.8%) with aspiration pneumonia, and one (0.9%) with pulmonary embolism.

When the indeterminate group was combined with the alternative diagnosis group, the sensitivity and specificity of the COVID-19 S were 93.9% and 96.0%, respectively, with 95.0% accuracy, 94.8% PPV and 95.2% NPV (Table 3).

When the indeterminate group was combined with the group compatible with COVID-19, the sensitivity and specificity of the COVID-19 S CT classification were 99.0% and 87.1%, respectively, with 92.3% accuracy, 85.8% PPV and 99.1% NPV (Table 3).

Discussion

COVID-19 has been spreading at a rapid rate across the world, causing the WHO to declare it a pandemic. Every day, large numbers of patients with infection or suspected infection present at hospitals. Since adequate testing capacity for SARS-CoV-2 is lacking worldwide, pandemic clinics are having difficulties with management, triage or therapy of these patients. In daily practice, radiology departments encounter a growing number of patients suspected of infection, even though chest CT is not recommended as the first-line diagnostic test.

Structured reporting is recommended as a solution to this excessive demand during the COVID-19 pandemic, since it facilitates radiological diagnosis, improves report quality by standardizing reporting language and reduces variability in the interpretation of CT reports by clinicians (14, 23). Still, radiologists are having difficulty with decision-making and reporting because the diversity of imaging findings is increasing with the number of cases and widespread use of CT. In particular, the high number of patients accumulating in the indeterminate group of the previously recommended classifications is a major problem; this leads to a delay in disease management. For this reason, a recent editorial by Kay et al. (24) encouraged researchers to focus on the many faces of COVID-19, for its better recognition and accurate diagnosis.

Based on the current literature, Radiological Society of North America proposed a standardized CT reporting language when radiologists are specifically asked to address whether findings of COVID-19 pneumonia are present in an endemic area. Typical appearances of COVID-19 pneumonia described in this proposed reporting are bilateral, peripheral GGOs with or without consolidation or visible intralobular lines and multifocal GGOs of rounded morphology with or without consolidation or visible intralobular lines. Unilateral GGO with or without consolidation lacking a specific distribution and are non-rounded or non-peripheral and few very small GGO with a non-rounded and non-peripheral distribution are described as indeterminate appearance. Consistent with the literature, most typical CT characteristics detected had involvement of all five lobes (64.3%), and predominant distribution in the middle and lower zones (44.9%), followed by lower zone predominance (29.6%), and peripheral and bronchocentric location of the lesions (66.3%) (17). However, our study demonstrated that although COVID-19 lesions are mostly bilateral and multilobar, they may be unilateral in the early stage of the disease, presenting especially in the form of GGO. In this study, five patients had unilateral elementary lesions, four in the lower zone only, and one in the middle and lower zones. Out of these five patients, two with elementary lesions in the lower zone were COVID-19. For this reason, single or multiple elementary COVID-19 lesions in a single middle-lower zone were classified as indeterminate in this study. On the other hand, radiologists should be aware that unilateral lesions related with COVID-19 are

Table 1. Description of the CT characteristics of an elementary COVID-19 lesion and explanation of the COVID-19 S CT classification system used in this study

COVID-19 S CT classification	CT findings
Normal	No CT features suggesting pneumonia
Compatible with COVID-19	• Bilateral elementary COVID-19 lesions* only / predominantly in lower zones (lower zones ± upper and middle zones) • Bilateral elementary COVID-19 lesions* in all zones without predominance
Indeterminate	• Bilateral elementary COVID-19 lesions* located predominantly in upper or middle zones • Single/multiple elementary COVID-19 lesions* in single lower zone unless consolidation is dominant • Unilateral elementary COVID-19 lesions* predominantly in lower zone • GGO which does not have the characteristic of elementary COVID-19 lesion but does not exactly fit any other diagnosis
Alternative diagnosis	• Elementary COVID-19 lesions* (single/multiple) in upper zones only • Unilateral elementary COVID-19 lesions* located predominantly in upper or middle zones • Absence of typical features of elementary COVID-19 lesion and presence of: o Infiltration that affects a large and continuous area of a lobe (lobar pneumonia) or infiltration of one or more secondary lobules of a lung presenting segmental consolidation (bronchopneumonia) o Bronchiolitis (tree-in-bud sign/centrilobular nodularity) o Cavitating infection o Bronchial wall thickening o Lymphadenopathy, pleural effusions o Smooth interlobular septal thickening

*Elementary COVID-19 lesion is defined as:

Pure GGO or GGO with consolidation (consolidation may be smaller in the central region of the lesion or may occupy most of the lesion [halo sign]) that has the fallowing characteristics:

- Rounded or lobulated or geographic contours (not diffuse)
- Discrete or coalescent
- Peripheral ± bronchocentric (not central)
- Predominantly posterior localization
- Accompanying intralesional intralobular reticulations (crazy paving) / bronchial dilatation / air bronchogram / vascular enlargement / air bubble/ curvilinear irregular thick lines / perilobular sparing / reverse halo sign

CT, computed tomography; COVID-19, coronavirus disease 2019; COVID-19 S, coronavirus disease 2019 structured reporting; GGO, ground glass opacity.

predominantly in the form of GGO since the disease is in an early stage. Thus, we recommend unilateral lesions in middle-lower zones to be classified as alternative diagnosis if consolidation is more extensive.

Another important finding of this study was that two of the COVID-19 patients demonstrated bilateral multilobar involvement in all zones, with upper zone predominance, and one of the COVID-19 patients demonstrated bilateral upper and middle zone involvement without predominance. Although studies report that COVID-19 is predominant in the middle and lower zones, this study demonstrated that upper zone predominance does not exclude diagnosis of COVID-19 if the lesions are bilateral. Based on these data, the lesions of these features were categorized as indeterminate group in this study. Still, by using the COVID-19 S CT diagnosis criteria, the proportion of indeterminate cases was only 7.2% (n=16).

When the indeterminate group was combined with the group compatible with COVID-19, the sensitivity (99.0%) and NPV (99.1%) were higher. On the other hand, the specificity (96.0%) and PPV (94.8%) were higher when the indeterminate group was combined with the alternative diagnosis group. Either way, the COVID-19 S showed superior performance to findings in previous literature. A recent study reported that the accuracies of three different radiologists in identifying COVID-19 from non-COVID-19 pneumonia were 83%, 80%, and 60%, and their sensitivities ranged from 72%–94% (11).

Table 2. Distribution of patients according to final clinical diagnosis and COVID-19 S CT classification system diagnosis

	Final clinical diagnosis		
COVID-19 S CT diagnosis	COVID-19	Non-COVID-19	Total
Compatible with COVID-19	92 (41.5)	5 (2.2)	97 (43.7)
Indeterminate	5 (2.2)	11 (5.0)	16 (7.2)
Alternative diagnosis	1 (0.5)	108 (48.6)	109 (49.1)
Total	98 (44.1)	124 (55.9)	222 (100.0)

Values are expressed as n (%).
COVID-19 S, coronavirus disease 2019 structured reporting; COVID-19, coronavirus disease 2019; CT, computed tomography.

Table 3. Sensitivity, specificity, predictive values and accuracy of the COVID-19 S CT classification system

COVID-19 S CT diagnosis	Sensitivity	Specificity	PPV	NPV	Accuracy
Compatible with COVID-19[a]	93.9% (92/98)	96.0% (119/124)	94.8% (92/97)	95.2% (119/125)	93.9% (211/222)
Compatible with COVID-19 and Indeterminate[b]	99.0% (97/98)	87.1% (108/124)	85.8% (97/113)	99.1% (211/222)	92.3% (205/222)

Values are expressed as % (n/N).
COVID-19 S, coronavirus disease 2019 structured reporting; CT, computed tomography; PPV, positive predictive value; NPV, negative predictive value.
[a] Kappa = 0.899, $P < 0.001$; [b]Kappa = 0.847, $P < 0.001$.

Another study reported that chest CT has approximately 56%–98% sensitivity in detecting COVID-19 at initial presentation (12, 25).

In this study, among 97 patients who were classified as compatible with COVID-19 upon chest CT findings under COVID-19 S, 92 (94.9%) had COVID-19 as a final clinical diagnosis. Despite this satisfactory accuracy in diagnosis, we re-evaluated these patients' CT scans. Surprisingly, we found that all of them had the most typical imaging characteristics of COVID-19 but were clinically not diagnosed as COVID-19 due to inconsistencies in the history, physical examination findings and RT-PCR and other laboratory test results. This finding is consistent with a previous study by Bai et al. (11), in which it was demonstrated that radiologists are capable of distinguishing COVID-19 from other types of pneumonia on chest CT with moderate sensitivity but high specificity. Similarly, in this study, out of 109 patients who were classified as alternative diagnosis under COVID-19 S, only one (0.9%) was COVID-19 and had atypical imaging findings described previously in the results.

Guan et al. (26) reported 230 out of 1099 cases (20.1%), Chuang et al. (27) reported three out of 21 cases (14.3%) and Yang et al. (4) reported 17 out of 149 cases (11.4%) having normal CT scans despite having COVID-19 diagnosis based on symptoms and RT-PCR test. In our study, among 581 patients with a normal chest CT scan, only 26 (4.5%) had a positive RT-PCR test result, since RT-PCR tests were not repeated for all of the patients in our study group because of the limited number of those tests at that time. Still, this finding demonstrates that a normal chest CT scan cannot exclude the diagnosis of COVID-19. Therefore, physicians should suspect patients with typical symptoms, laboratory test results, and exposure history, and consider RT-PCR testing.

One of the advantages of our study is that the patients were included consecutively regardless of the RT-PCR result. To our knowledge, most of the studies about imaging findings of COVID-19 include only RT-PCR-confirmed cases. Although the RT-PCR test is the standard diagnostic method of testing for COVID-19, it has a lower sensitivity of 65%–95%, meaning that the test can be negative even when the patient is infected (10, 11). The sensitivity of testing likely depends on the precise assay, the type of specimen obtained, the quality of the specimen, and duration of illness at the time of testing (28). For this reason, WHO declared that, one or more negative results do not rule out the possibility of COVID-19 virus infection in suspected cases (29). Hence, we suggest that the absence of a control group or lack of RT-PCR-negative cases may lead to a methodologic bias for a radiologic study, since an RT-PCR result may be false negative at the early stage of the disease, when imaging findings may be subtle, or at the late stage, when imaging findings may be obscure. Thus, we have included these types of patients who are difficult to classify.

Another advantage of this study, relating to the diagnosis, is that all the patients were evaluated by two physicians for the final diagnosis of COVID-19. Since it is known that the CT findings of COVID-19 may overlap with other diseases, such as other viral pneumonias including influenza, organized pneumonia, drug toxicity and connective tissue diseases, a differential diagnosis can only be made by the consultant physician. The evaluation of the patients by two physicians for the final diagnosis and comparison of the results showed us how accurately our classification system worked.

To our knowledge, this study is the first to use "elementary COVID-19 lesion" as the terminology for describing typical COVID-19 lesions detected by CT. Also, the COVID-19 S used in this study is the first CT classification presenting a figurative description for diagnosis of COVID-19.

The small cohort size was a limitation of our study. We suggest that conducting this study with a larger cohort may help with developing a better CT classification of diagnosis and reduce the number of cases with an indeterminate CT diagnosis. We would like to emphasize that SARS-CoV-2 is a novel virus with lots of unknowns, and the current knowledge on COVID-19 is subject to change. In cases where RT-PCR tests are negative and there is a strong suspicion of COVID-19 infection, paired serum samples could support diagnosis. Another limitation of this study is that serological data on clinical samples of the patients was not known since validated serology tests were not available in our hospital when this research was done. Finally, pediatric patients were not included in the study since symptomatic infection in children appears to be uncommon. However, lack of information on how the disease presents on CT in pediatric patients may be considered as a limitation of the study.

In conclusion, COVID-19 S, which was used as the classification system for CT findings of COVID-19 in this study, may meet the needs of radiologists in distinguishing COVID-19 from pneumonia of other etiologies and help optimize patient management and disease control in this pandemic by the use of structured reporting.

Acknowledgments

The authors would like to thank Prof. Dr. Hülya Ellidokuz for assisting with statistical data and, Prof. Dr. Handan Güleryüz and Prof. Dr. Mustafa Seçil for their contribution to the organization of this work.

Conflict of interest disclosure

The authors declared no conflicts of interest.

References

1. Sahu KK, Mishra AK, Lal A. Comprehensive update on current outbreak of novel coronavirus infection (2019-nCoV). Ann Transl Med 2020; 8:393. [Crossref]
2. Sahu KK, Mishra AK, Lal A. Novel coronavirus (2019-nCoV): update on 3rd coronavirus outbreak of 21st century. QJM 2020 Mar 3. [Epub ahead of print] [Crossref]
3. Hui DS, Azhar EI, Madani TA, et al. The continuing 2019-nCoV epidemic threat of novel coronaviruses to global health–The latest 2019 novel coronavirus outbreak in Wuhan, China. Int J Infect Dis 2020; 91:264–266. [Crossref]
4. Yang W, Cao Q, Qin L, et al. Clinical characteristics and imaging manifestations of the 2019 novel coronavirus disease (COVID-19): A multi-center study in Wenzhou city, Zhejiang, China. J Infect 2020; 80:388–393. [Crossref]
5. WHO Director-General's opening remarks at the media briefing on COVID-19. World Health Organization (WHO) (Press release). March 11, 2020. Retrieved 2020 March 12, 2020. Available at: https://www.who.int/dg/speeches/detail/who-director-general-s-opening-remarks-at-the-media-briefing-on-covid19---27-march-2020.
6. European Centre for Disease Prevention and Control. COVID-19 situation update worldwide, as of 26 May 2020. Available at: https://www.ecdc.europa.eu/en/geographical-distribution-2019-ncov-cases.
7. Zhang N, Wang L, Deng X, et al. Recent advances in the detection of respiratory virus infection in humans. J Med Virol 2020; 92:408–417. [Crossref]
8. Ai T, Yang Z, Hou H, et al. Correlation of chest CT and RT-PCR testing in coronavirus disease 2019 (COVID-19) in China: A report of 1014 cases. Radiology 2020; 26:200642. [Crossref]
9. Li Y, Yao L, Li J, et al. Stability issues of RT-PCR testing of SARS-CoV-2 for hospitalized patients clinically diagnosed with COVID-19. J Med Virol 2020 Mar 26. [Epub ahead of print] [Crossref]
10. Centers for Disease Control and Prevention. 2019 novel coronavirus (2019-nCoV) situation summary. Available at: https://www.cdc.gov/coronavirus/2019-ncov/index.htm 2020 Jan 3. Archived from the original on 2020 Jan 26.
11. Bai HX, Hsieh B, Xiong Z, et al. Performance of radiologists in differentiating COVID-19 from viral pneumonia on chest CT. Radiology 2020 Mar 10:200823. [Crossref]
12. Fang Y, Zhang H, Xie J, et al. Sensitivity of chest CT for COVID-19: comparison to RT-PCR. Radiology 2020:200432. [Crossref]
13. An P, Ye Y, Chen M, Chen Y, Fan W, Wang Y. Management strategy of novel coronavirus (COVID-19) pneumonia in the radiology department: a Chinese experience. Diagn Interv Radiol 2020 Mar 25. [Epub ahead of print]
14. British Society of Thoracic Imaging. Version 2. Thoracic imaging in COVID-19 Infection. Guidance for the reporting radiologist. Available at: https://www.bsti.org.uk/standards-clinical-guidelines/clinical-guidelines/COVID-19-bsti-statement-andguidance/. Epub 2020 Apr 4.
15. Rubin GD, Ryerson CJ, Haramati LB, et al. The role of chest imaging in patient management during the COVID-19 pandemic: a multinational consensus statement from the Fleischner Society. Chest 2020 Apr 7. [Epub ahead of print] [Crossref]
16. Simpson S, Kay FU, Abbara S, et al. Radiological Society of North America Expert Consensus Statement on Reporting Chest CT Findings Related to COVID-19. Endorsed by the Society of Thoracic Radiology, the American College of Radiology, and RSNA. J Thorac Imaging 2020 Apr 28. [Epub ahead of print] [Crossref]
17. Li Y, Xia L. Coronavirus disease 2019 (COVID-19): role of chest CT in diagnosis and management. AJR Am J Roentgenol 2020; 4:1–7. [Epub ahead of print] [Crossref]
18. Sahu KK, Lal A, Mishra AK. An update on CT chest findings in coronavirus disease-19 (COVID-19). Heart Lung 2020 Mar 20. [Epub ahead of print] [Crossref]
19. Li K, Fang Y, Li W, Pan C, Qin P, Zhong Y, et al. CT image visual quantitative evaluation and clinical classification of coronavirus disease (COVID-19). Eur Radiol 2020 Mar 25. [Epub ahead of print] [Crossref]
20. Ye Z, Zhang Y, Wang Y, Huang Z, Song B. Chest CT manifestations of new coronavirus disease 2019 (COVID-19): a pictorial review. Eur Radiol 2020 Mar 19. [Epub ahead of print] [Crossref]
21. Huang G, Gong T, Wang G, et al. Timely diagnosis and treatment shortens the time to resolution of coronavirus disease (COVID-19) pneumonia and lowers the highest and last CT scores from sequential chest CT. AJR Am J Roentgenol 2020; 30:1–7. [Crossref]
22. Hansell DM, Bankier AA, MacMahon H, McLoud TC, Muller NL, Remy J. Fleischner society: glossary of terms for thoracic imaging. Radiology 2008; 246:697–722. [Crossref]
23. American College of Radiology. CR Recommendations for the use of chest radiography and computed tomography (CT) for suspected COVID-19 infection. Available at: https://www.acr.org/Advocacy-and-Economics/ACR-Position-Statements/Recommendations-for-Chest-Radiography-and-CT-for-Suspected-COVID19-Infection. Epub 2020 Mar22.
24. Kay F, Abbara S. The many faces of COVID-19: spectrum of imaging manifestations. Radiol Cardiothorac Imaging 2020, Feb 14. [Epub ahead of print] [Crossref]
25. Kanne JP, Little BP, Chung JH, Elicker BM, Ketail LH. Essentials for radiologists on COVID-19: an update—Radiology Scientific Expert Panel. Radiology 2020 Feb 27. [Epub ahead of print] [Crossref]
26. Guan W, Ni Z, Hu Y, et al. Clinical characteristics of 2019 novel coronavirus infection in China. BMJ 2020 Feb 09. [Epub ahead of print]
27. Chung M, Bernheim A, Mei X, et al. CT Imaging features of 2019 novel coronavirus (2019-nCoV). Radiology 2020; 295:202–207. [Crossref]
28. Kenneth McIntosh. Coronavirus disease 2019 (COVID-19): Epidemiology, virology, clinical features, diagnosis, and prevention. Apr 2020. This topic last updated: May 22, 2020. Available at: https://www.uptodate.com/contents/coronavirus-disease-2019-COVID-19-epidemiology-virology-clinical-features-diagnosis-and-prevention.
29. World Health Organization. Laboratory testing for coronavirus disease 2019 (COVID-19)in suspected human cases: interim guidance, 2 March 2020. Available at: https://apps.who.int/iris/handle/10665/331329.