DOI:10.14744/bej.2017.43531
Beyoglu Eye J 2017; 2(2): 71-75

Case Report

Posterior Scleritis after Extraocular Horizontal Muscle Transposition Surgery: A Case Report

Osman Bulut Ocak, Asli Inal, Ebru Demet Aygit, Ihsan Yilmaz, Ahmet Demirok, Birsen Gokyigit

University of Health Sciences Beyoglu Eye Training and Research Hospital, Istanbul, Turkey

Abstract

A male patient was diagnosed with bilateral congenital third nerve palsy when he presented at the clinic for the first time in 2001 at the age of 22 with the complaints of decreased visual acuity in the right eye, exodeviation, and movement disability in the medial, upper, and inner gaze. The right eye was diagnosed with anterior segment ischemia and stem cell deficiency, which had developed after strabismus surgery. Lateral rectus (LR) augmented recession and conjunctival recession were performed in the left eye of the patient in 2001. The clinical follow-up was completed. The patient presented at the clinic again in 2014. In 2015, the left LR was transposed to the medial rectus region after being divided in 2 with a Y-split. The inferior part was passed under the inferior rectus and inferior oblique muscles, and the superior part was passed under the superior rectus and superior oblique muscles. When the patient described reduced vision on the postoperative first day, fundus examination was performed, followed by fundus fluorescein angiography. Optical coherence tomography findings were assessed and posterior scleritis was diagnosed. Medical treatment was planned and the case was closely monitored. Posterior scleritis had resolved at the fourth month after the operation. At the last visit, it was observed that preoperative visual acuity values and orthophoria in the primary position had been achieved.

Keywords: Muscle transposition, scleritis, strabismus surgery.

Introduction

Strabismus surgery complications that threaten visual acuity, such as scleral perforation, scleral dellen, endophthalmitis, central serous chorioretinopathy, or scleritis, can occur intra- or postoperatively (1). These complications are more often seen in extraocular muscle transposition surgeries (2, 3). Presently described is a case of posterior scleritis developing after extraocular muscle transposition surgery for congenital third nerve palsy.

Case Report

In March 2001, a 22-year-old male presented at the clinic with low visual acuity in the right eye, exotropia, and limited ocular movement in both eyes. The best-corrected visual acuity (BCVA) was finger counting at 1 m for the right eye and at 0.7 m for the left. Biomicroscopic examination revealed total corneal vascularization in the right eye. Funduscopic examination of the right eye showed just reflection, whereas the left eye was normal. Cycloplegic refraction results for the left eye were +0.00 D (-1.75−160), but the right eye could not be measured. When eye movements were examined, it was observed that ocular movements were limited in all positions, and that both eyelids were ptotic. The ptosis was greater on the right side. The Krimsky prism test result in the primary position was 90 prism diopters (PD) exotropia. The medical history of the patient indicated that he had congenital exotropia in both eyes and had undergone strabismus

Address for correspondence: Osman Bulut Ocak, MD. Beyoglu Goz Egitim ve Arastirma Hastanesi, Bereketzade Cami Sokak, 34421 Beyoglu, Istanbul, Turkey
Phone: +90 212 251 59 00 **E-mail:** bulutocak@gmail.com
Submitted Date: July 22, 2017 **Accepted Date:** September 11, 2017 **Available Online Date:** October 16, 2017
©Copyright 2017 by Beyoglu Eye Training and Research Hospital - Available online at www.beyoglueye.com

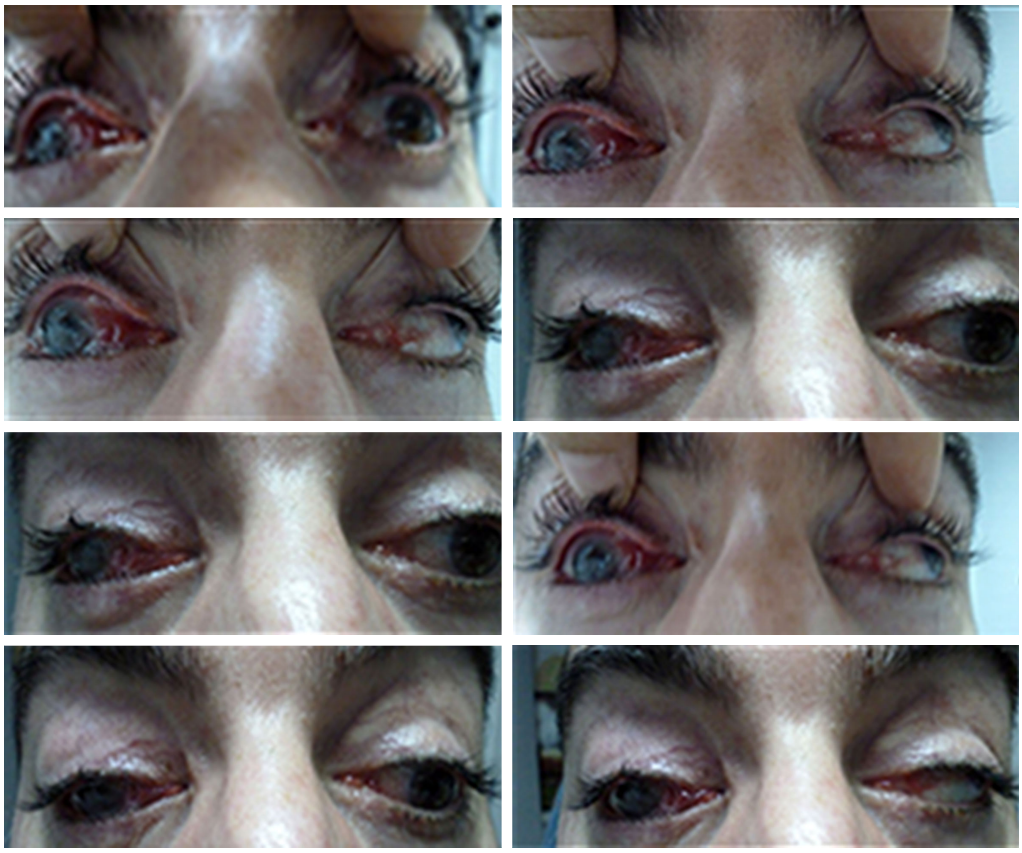

Figure 1. Preoperative primary position of gaze.

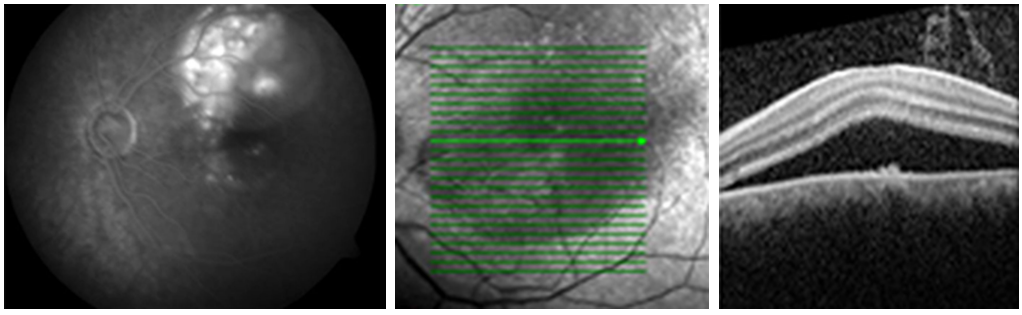

Figure 2. Postoperative second week early arteriovenous and late phases of fluorescein angiography and optical coherence tomography images.

surgery when he was 9 years old. There was no systemic disease. The diagnosis was bilateral congenital third nerve palsy. Corneal vascularization in the right eye was thought to be caused by stem cell deficiency due to anterior segment ischemia. Lateral rectus (LR) augmented recession (10 mm) and conjunctival recession (CR) were performed on the left eye in April 2001. In the postoperative third month, 45 PD exotropia was measured in the left eye using the Krimsky prism test. Follow-up was terminated after the third month control visit.

The patient returned to the clinic in August 2014 at 35 years of age. BCVA, biomicroscopic and funduscopic examinations, and cycloplegic refraction results were similar to those seen in 2001. Limited ocular movements were observed, and the Krimsky prism test measured 80 PD exotropia (Fig. 1). Strabismus surgery was planned for the left eye in January 2015. During the operation, the left eye LR was found to be 10 mm behind its original insertion. The LR was divided in 2 with a Y-split. The upper branch of the LR was passed under the superior rectus and superior oblique muscles, and the lower branch was passed under the inferior rectus and inferior oblique muscles. It was then transposed with the original insertion of the left medial rectus with 6-0 non-absorbable suture using the hang-back technique.

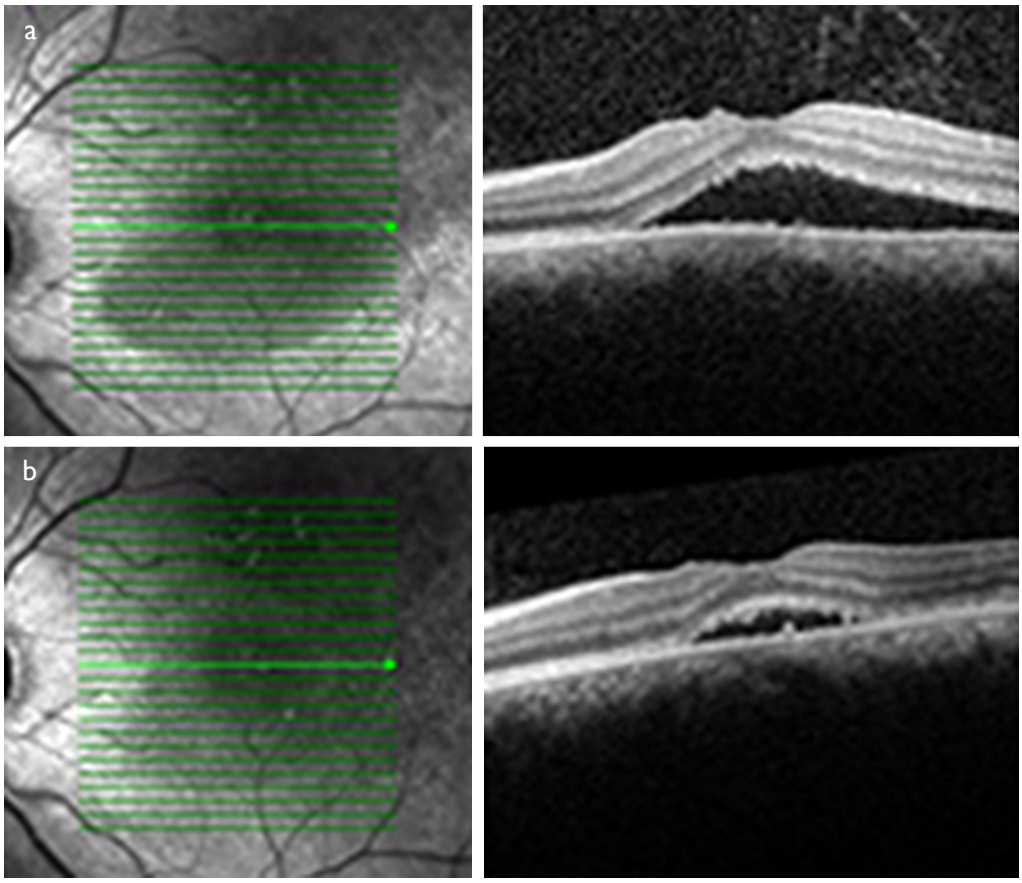

Figure 3. (a) Postoperative fourth week optical coherence tomography image. **(b)** Postoperative 10th week optical coherence tomography image.

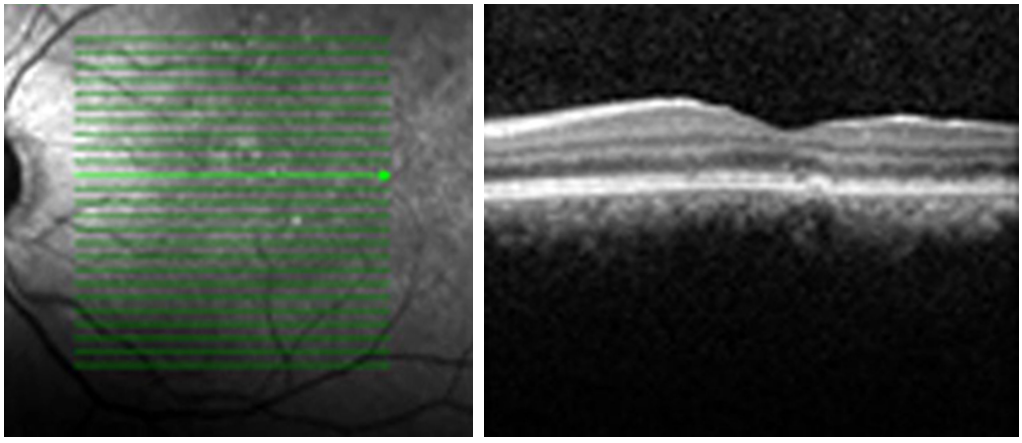

Figure 4. Postoperative 14th week optical coherence tomography image.

On the postoperative first day, the left eye was orthophoric in the primary position, but the patient described blurred vision in the eye. The BCVA was determined to be 0.5 in the left eye. Subretinal fluid on the superior of the macula was observed using direct ophthalmoscopy. Topical nonsteroidal anti-inflammatory (NSAI) nepafenac 4 times a day and systemic NSAI diclofenac sodium tablet 75 mg 2 times a day were prescribed.

At the postoperative 2nd week control visit, the left eye BCVA was 0.4, and fundus fluorescein angiography (FFA) and spectral domain optical coherence tomography (SD-OCT) were performed for retinal imaging. In the early arteriovenous phase of FFA, there was a hyperfluorescent spot at the superior temporal quadrant. In the late phase, a well-bordered, patchy, hyperfluorescent area was seen. A large area of subretinal fluid was seen in the baseline SD-OCT scan

Figure 5. Postoperative 6th month primary position of gaze.

(Fig. 2). Following FFA and SD-OCT, posterior scleritis was diagnosed. Topical prednisolone acetate 4 times a day and systemic prednisolone 64 mg/day were prescribed for treatment. The case was monitored weekly.

At the postoperative fourth week control visit, follow-up FFA and SD-OCT revealed retained subretinal fluid (Fig. 3a). BCVA had increased to 0.5. Systemic prednisolone was reduced 48 mg/day. The subretinal fluid was observed to lessen steadily at subsequent control visits (Fig. 3b). Systemic steroid was reduced to 16 mg/day at the 8th and 10th postoperative weeks.

At the postoperative 14th week control visit, the subretinal fluid had disappeared completely (Fig. 4). At the postoperative fourth month, BCVA level was measured as 0.6 and treatment was completed. At the postoperative sixth month, BCVA was 0.6, and the left eye was orthophoric in the primary position (Fig. 5).

Conclusion

Total oculomotor nerve paralysis is the most difficult group for surgical treatment when compared with other types of ocular motor nerve paralysis. The surgical treatment goal is to achieve a reasonable cosmetic appearance in the primary position, and to help the patient regain binocular visual function (3). Extraocular horizontal and/or vertical muscle transposition operations are performed with these objectives in mind (3, 4).

Scleral perforation and retinal detachment, central serous chorioretinopathy, scleritis, endophthalmitis, and orbital cellulitis are serious potential complications of strabismus surgery (1).

Surgically induced scleral necrosis (SINS) was described by Arentsen in 1976, and published in the literature with a 52-case study conducted by O'Donoghue et al. (5). In this study, it was stated that it could occur after any eye operation, such as glaucoma, cataract, strabismus, or retinal detachment surgery, and that the treatment is immunosuppressive therapy (5). In our case, the posterior scleritis had receded at the postoperative fourth month following administration of immunosuppressive therapy. In the instance that the patient does not respond to immunosuppressive treatment, some studies have recommended scleral patches or topical N-acetylcysteine (6, 7).

In strabismus surgery, and particularly for extraocular muscle transposition surgery, scleral and retinal complications, which may lead to permanent visual loss, must be considered at all times.

Disclosures

Peer-review: Externally peer-reviewed.

Conflict of Interest: None declared.

Authorship Contributions: Involved in design and conduct of the study (OBO, AI, EDA, AD, BG); preparation and review of the study (OBO, BG, AI, IY); data collection (AI, BG).

References

1. Bradbury JA, Taylor RH. Severe complications of strabismus surgery. J AAPOS 2013;17:59–63.
2. Sorenson R, Soni A. Central serous chorioretinopathy following medial transposition of split lateral rectus muscle for complete oculomotor nerve palsy. J AAPOS 2017;21:161–2.
3. Gokyigit B, Akar S, Satana B, Demirok A, Yilmaz OF. Medial transposition of a split lateral rectus muscle for complete oculomotor nerve palsy. J AAPOS 2013;17:402–10.
4. Erbagci I, Öner V, Coskun E, Okumus S. A New Surgical Treatment Option for Chronic Total Oculomotor Nerve Palsy: A Modified Technique for Medial Transposition of Split Lateral Rectus Muscle. J Pediatr Ophthalmol Strabismus 2016;53:150–4.
5. O'Donoghue E, Lightman S, Tuft S, Watson P. Surgically induced necrotising sclerokeratitis (SINS)-precipitating factors and response to treatment. Br J Ophthalmol 1992;76:17–21.
6. Huang CY, Lin HC, Yang ML. Necrotizing scleritis after strabis-

mus surgery in thyroid eye disease. J AAPOS 2013;17:535–6.
7. Rajamani M, Nagasubramanian V, Ayyavoo A, Raghupathy P, Dandapani R. Surgically Induced Necrotizing Scleritis Following Strabismus Surgery Treated Successfully with Topical N-acetylcysteine in a Child with Congenital Fibrosis of Extraocular Muscles and Varadi Papp Syndrome. Strabismus 2017;25:39–42.