DOI:10.14744/bej.2019.00710
Beyoglu Eye J 2019; 4(2): 115-119

Original Article

Ciliary Sulcus Implantation of Ahmed Glaucoma Valve in Patients with Corneal Decompensation Risk

Serhat Imamoglu, Nimet Yesim Ercalik, Buse Guneri Beser, Nimet Burcu Celik

Department of Ophthalmology, Haydarpasa Numune Training and Research Hospital, Istanbul, Turkey

Abstract

Objectives: The goal of this study was to examine the safety and efficacy of ciliary sulcus implantation of the Ahmed glaucoma valve (AGV; New World Medical, Inc., Rancho Cucamonga, CA, USA) in patients with a risk of corneal decompensation.

Methods: Patients with a corneal decompensation risk who underwent AGV implantation at a single institution were included in this retrospective study. The patients' preoperative intraocular pressure (IOP), best corrected visual acuity (BCVA), and the number of anti-glaucomatous eye drop medications used was compared with postoperative values. The success criteria were defined as a postoperative IOP of 5 to 21 mmHg and no loss of light perception.

Results: Twenty-three eyes of 23 (16 male, 7 female) patients were included in the study. The mean age of the patients was 64.6±14.6 years and the mean follow-up period was 15.8±8.3 months. The preoperative mean IOP was reduced from 33.6±9.1 mmHg to 16.9±5.1 mmHg at the last follow-up (p=0.000). The mean preoperative number of anti-glaucomatous eye drop medications used was 3.5±1.3. Postoperatively the mean was 1.7±1.4 at the last follow-up (p=0.000). The rate of total success was determined to be 78%. The postoperative mean BCVA did not change significantly. One patient lost light perception. A decrease in corneal clarity was observed in only 1 patient (4.3%). The postoperative complications observed were: bleb encapsulation (43%), hyphema (39%), tube occlusion (13%), choroidal detachment (8.7%), decompression retinopathy (8.7%), and corneal decompensation (4.3%).

Conclusion: Ciliary sulcus implantation of an AGV was effective, both in terms of IOP and the decrease in anti-glaucomatous drug use in the short term. This technique may be a good choice in patients with a corneal decompensation risk due to the posterior chamber implantation.

Keywords: Ahmed glaucoma valve, ciliary sulcus, corneal decompensation.

Introduction

Glaucoma drainage devices are used to provide for a flow of aqueous humor from the anterior chamber to the subconjunctival space in glaucoma cases when treatment with standard filtration surgery is difficult (1). The Ahmed glaucoma valve (AGV; New World Medical, Inc., Rancho Cucamonga, CA, USA) is the most widely used drainage device in ophthalmology due to the ease of use and success in postoperative intraocular pressure (IOP) control (2, 3).

It has been suggested that tube–endothelial contact that may occur during eye rubbing, eye movement, and blinking may cause corneal endothelial decompensation in cases where an AGV tube has been inserted through the anterior chamber angle (4, 5). Several studies have reported a rate of between 7% and 27% (6–9). Tube implantation into the pars plana or ciliary sulcus has been investigated as a possible means of reducing contact in cases with a risk of corneal decompensation or peripheral anterior synechiae (PAS) (4,

Address for correspondence: Serhat Imamoglu, MD. Haydarpasa Numune Egitim ve Arastirma Hastanesi, Oftalmoloji Anabilim Dali, Istanbul, Turkey
Phone: +90 216 542 44 44 **E-mail:** ophserhat@hotmail.com

Submitted Date: August 31, 2018 **Accepted Date:** May 22, 2019 **Available Online Date:** August 19, 2019

©Copyright 2019 by Beyoglu Eye Training and Research Hospital - Available online at www.beyoglueye.com
OPEN ACCESS This work is licensed under a Creative Commons Attribution-NonCommercial 4.0 International License.

10–12). AGV insertion into the ciliary sulcus has been proposed as a more advantageous option because AGV insertion into the pars plana is thought to be associated with more posterior segment complications and more additional inflammation following vitrectomy (13).

This study is an examination of the clinical outcomes and complications of AGV tube insertion into the posterior chamber ciliary sulcus in cases with a risk of corneal decompensation.

Methods

The records of 23 patients at our eye clinic from between 2012 and 2018 who did not respond to medical glaucoma therapy or classic filtration surgery and who underwent AGV tube insertion in the ciliary sulcus due to the risk of corneal decompensation were retrospectively evaluated. Cases with a history of multiple ocular surgery or penetrating keratoplasty, a narrow anterior chamber, corneal guttata, corneal edema, or PAS were included in the study. AGV tube insertion into the ciliary sulcus was preferred in these cases due to the risk of corneal decompensation following tube insertion into the anterior chamber.

Cases with fewer than 6 months of follow-up data, or with an anterior chamber lens or active uveitis were excluded from the study. Surgical success was defined as an IOP that remained in the range of 5 to 21 mmHg with or without medication and no loss of light perception. Complete success was defined as obtaining these results without the need for anti-glaucomatous eye drops, while partial success was defined as obtaining these results with the use of anti-glaucomatous eye drops.

A best corrected visual acuity (BCVA) assessment using the Snellen chart, IOP measurement, and the results of anterior and posterior segment examination with biomicroscopy and gonioscopy were recorded for all patients. Corneal edema was evaluated with biomicroscopy: The presence of central corneal guttata and the beaten-metal appearance of Descemet's membrane were considered stage 1 corneal edema, epithelial and stromal edema were assessed as stage 2, and the presence of bullae and wrinkles of Descemet's membrane were considered stage 3. Corneal decompensation was evaluated according to corneal thickness. IOP measurements were performed with an Icare tonometer (Tiolat Oy, Helsinki, Finland) in patients with a history of penetrating keratoplasty surgery, while a Goldmann applanation tonometer (Haag-Streit AG, Köniz, Switzerland) was used in the remaining cases. The same device was used to measure IOP during control examinations.

All of the operations were performed by the same surgeon (SI) using sub-Tenon or general anesthesia. In combined cases, cataract surgery was performed before the glaucoma procedure. In cases with neovascular glaucoma, an intracameral injection of 1.25 mg bevacizumab (Avastin; Genentech Inc., South San Francisco, CA, USA) was administered 2 to 7 days prior to the AGV implantation.

An AGV was implanted using a long scleral tunnel technique in either the upper temporal quadrant (Fig. 1) or the

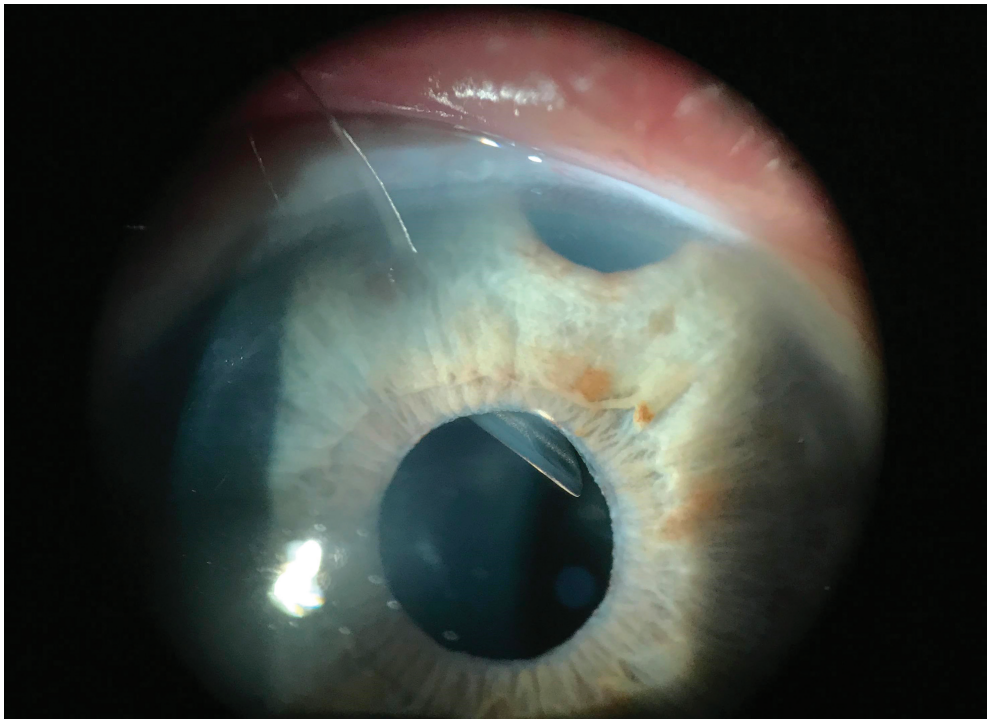

Figure 1. Ahmed Glaucoma Valve tube seen on superotemporal quadrant (Postoperative 6 month anterior segment photo).

upper nasal quadrant, if the conjunctiva was more mobile (especially preferred in patients with low vision potential in order to prevent diplopia). At the conclusion of the operation, 0.1 mL of moxifloxacin was administered into the anterior chamber. The patients were treated with moxifloxacin and prednisolone eye drops postoperatively. Drops were used for 10 to 12 weeks until wound healing was complete and the inflammation reduced. Additional anti-glaucomatous treatment was initiated when needed. Postoperative controls were performed on the first day and at 1 week postoperatively, and again at 1, 2, 3, 6 months, and continued thereafter. Figure 1 is an anterior segment photograph of a patient with an AGV tube implantation in the ciliary sulcus.

SPSS Statistics for Windows, Version 17.0 (SPSS Inc., Chicago, IL, USA) was used for the statistical analysis. Normal distribution of the parameters was assessed using the Shapiro–Wilk test. The difference between preoperative and postoperative values was assessed using the Wilcoxon test. It was considered statistically significant when the p value was less than 0.05.

Results

Twenty-three eyes of 23 patients (16 males and 7 females) were included in the study. The mean age of the study participants was 64.6±14.6 years and the mean length of follow-up was 15.8±8.3 months. Eight cases had previously undergone glaucoma surgery. The demographic characteristics of the cases and the indications of AGV are shown in Table 1.

Twenty-one (91.3%) cases were treated with AGV implantation alone, while phacoemulsification surgery and posterior chamber intraocular lens implantation were also performed in 2 cases. Seven patients with neovascular glaucoma had an intracameral injection of bevacizumab in the preoperative period.

The mean IOP had tapered from 33 mmHg to 16.9 mmHg at the last visit. The mean number of anti-glaucomatous eye drops medications used was 3.5±1.3 in the preoperative period, while it was 1.7±1.4 at the last postoperative examination (p=0.000).

The median BCVA was measured at 1.8 LogMAR (range: 0.52–3.1 LogMAR) in the preoperative period and 1.8 LogMAR (range: 0.55–2.1 LogMAR) in the postoperative period. Light perception was lost in 1 patient whose IOP could not be appropriately controlled postoperatively.

Surgical success was achieved in 18 (78%) cases. Complete success was achieved in 7 (31%) cases, while partial success was achieved in 11 (47%). A graph depicting the postoperative success rate evaluated with Kaplan–Meier analysis is displayed in Figure 2.

The postoperative complications observed were bleb encapsulation (43%), hyphema (39%), tube blockage (13%), choroidal detachment (8.7%), decompression retinopathy (8.7%), and corneal decompensation (4.3%). Eight (34.7%) patients had edema preoperatively, either in the cornea or in the graft tissue. Three (13%) of these cases did not experience a postoperative increase in edema. In 1 patient (4.3%) with iridocorneal endothelial syndrome, the corneal edema progressed and penetrating keratoplasty was required.

Subconjunctival needling with 5-fluorouracil (0.1 mL in 50 mg/mL) was performed in all instances of bleb encapsulation. In one case (4.3%), additional bleb revision was performed. Hyphema was usually reduced with medical treatment; an-

Table 1. Demographic characteristics of the patients

Age (years)	64.6±14.6 (24-85)
Sex	
Male	16 (%69.6)
Female	9 (%30.4)
Previous glaucoma surgery	8 (%34.8)
Preoperative IOP	3.5±1.3
Preoperative BCVA (median [interquartile range])	1.8 (0.52-3.1)
Glaucoma etiology	
NVG	7 (%30.4)
PK	3 (%13)
Post PPV	2 (%8.7)
OAG (primary, PEX, Fuch's, steroid-induced)	10 (%43.5)
Angle closure (ICE syndrome)	1 (%4.3)

BCVA: best corrected visual acuity; ICE: iridocorneal endothelial; IOP: intraocular pressure; NVG: neovascular glaucoma; OAG: open-angle glaucoma; PEX: pseudoexfoliation; PK: penetrating keratoplasty; PPV: pars plana vitrectomy.

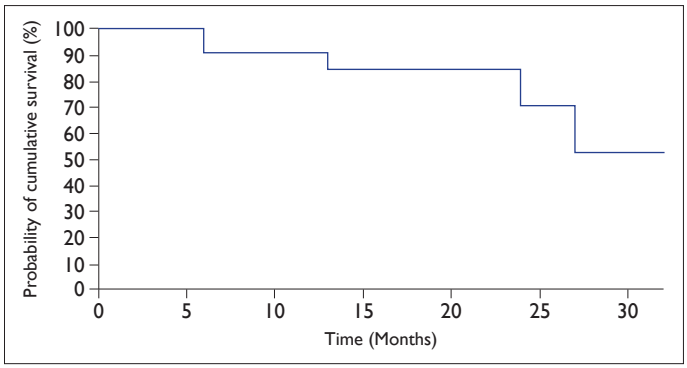

Figure 2. Cumulative survival rate graph of patients during follow-up period (Kaplan-Meier).

terior chamber lavage was needed in only 1 (4.3%) case. One (4.3%) patient with tube blockage underwent revision surgery. The posterior segment complications seen were choroidal detachment in 2 (8.7%) cases and decompression retinopathy in another 2 (8.7%). These complications were improved with medical treatment. Removal of the AGV was not required in any patient.

Discussion

Placement of a glaucoma tube in the anterior chamber may increase corneal endothelial damage, corneal decompensation, and graft rejection, especially in eyes with a narrow anterior chamber, due to the tendency to move toward the cornea over time (14). A reduction in the number of endothelial cells by 20% 2 years after tube implantation in the anterior chamber has been reported (15). By placing the tube in the ciliary sulcus, the end of the tube is as far from the cornea as possible and prevented from touching the cornea (11, 16).

An AGV placed in the ciliary sulcus was observed to provide effective IOP control in our study. The success rate of our series was determined to be 78%. Eslami et al. (10) reported a success rate of 78.6%, and Bayer et al. (16) recorded a rate of 85.3%. However, different patient groups, different types of glaucoma, and different success criteria make it impossible to compare the studies directly.

The most common complication in our cases was bleb encapsulation, seen in 43% of patients. We associate this high rate with the change in the conjunctival surface due to previous operations. It has been reported that bleb encapsulation can be triggered by effects related to the previous conjunctival surface and subsequent surgical stimulation of fibrous proliferation (17).

The second most common complication in our study was hyphema, seen in 39% of cases. In the literature, hyphema has been reported to occur in 8% to 16.9% of patients after implantation of the AGV tube in the anterior chamber angle or pars plana (18–21). In their study of AGV tube implantation in the ciliary sulcus, Bayer et al. (10) found a ratio of hyphema of 14.3%. The greater vascularization of the ciliary sulcus compared with the anterior chamber angle or pars plana may have contributed to these findings (13).

Bevacizumab has been shown to be effective in reducing iris neovascularization in neovascular glaucoma (NVG) cases with ciliary sulcus tube implantation (22). We also observed better control of IOP in the early period and regression of iris neovascularization in our cases with NVG when an intracameral bevacizumab injection had been administered prior to AGV implantation. It may be that anti-vascular endothelial factor agents applied in the preoperative period can increase the comfort of the procedure.

Corneal transparency did not decrease postoperatively in our study, with the exception of 1 case with iridocorneal endothelial syndrome. Similarly, Eslami et al. (16) did not encounter this complication in their study of tube implantation in the ciliary sulcus. Nonetheless, specular microscopic examination, a longer follow-up period and a broader series of patients are needed to better investigate the effect on endothelial function of tubes placed into the ciliary sulcus. Few serious posterior segment complications have been reported in studies examining AGV tube implantation into the ciliary sulcus (23, 24). Choroidal detachment was seen in 8.7% of cases in our study, and it improved with medical therapy. This result is consistent with the choroidal detachment rate (8.7%) seen in the research of Eslami et al. (16).

Neither anterior uveitis nor iris pigment dispersion was observed in any of our study participants, despite the closeness of the tube and the iris. However, we still think that AGV tube implantation into the ciliary sulcus should be avoided in cases with active uveitis.

The limitations of our study are its retrospective design, the small number of cases, short follow-up period, lack of a control group (anterior chamber implantation), and lack of specular microscopic examination. Furthermore, the patient group was not etiologically homogenous.

Implantation of an AGV tube into the ciliary sulcus resulted in a significant decrease in IOP and a reduction in the number of anti-glaucomatous drugs in a short time. In addition, corneal decompensation developed postoperatively in only 1 case. In order to better evaluate the safety and efficacy of AGV tube implantation in the ciliary sulcus, there is a need for studies with a larger patient group and data that are supported by specular microscopy.

Disclosures
Ethics Committee Approval: Haydarpaşa Numune Training and Research Hospital, HNEAH-KAEK2016/KK/103, 2016
Peer-review: Externally peer-reviewed.

Conflict of Interest: None declared.

Authorship Contributions: Involved in design and conduct of the study (SI, NYE, BGB); preparation and review of the study (SI, NYE, NBC); data collection (S.I., NYE, BGB); and statistical analysis (SI, NYE, NBC).

References

1. Şatana B, Yalvaç I, Kasım R, Duman S. İleri glokom olgularında Molteno tüp ve Ahmed glokom valv implantının klinik sonuçlarının değerlendirilmesi. T Oft Gaz 2002;32:100–6.
2. Coleman AL, Hill R, Wilson MR, Choplin N, Kotas-Neumann R, Tam M, et al. Initial clinical experience with the Ahmed Glaucoma Valve implant. Am J Ophthalmol 1995;120:23–31.
3. Huh KC, Kee CW. A clinical analysis of the Ahmed glaucoma valve implant with or without partial ligation of silicone tube. J Korean Ophthalmol Soc 2000;41:2611–7.
4. Sidoti PA, Mosny AY, Ritterband DC, Seedor JA. Pars plana tube insertion of glaucoma drainage implants and penetrating keratoplasty in patients with coexisting glaucoma and corneal disease. Ophthalmology 2001;108:1050–8.
5. Kwon YH, Taylor JM, Hong S, Honkanen RA, Zimmerman MB, Alward WL, et al. Long-term results of eyes with penetrating keratoplasty and glaucoma drainage tubeimplant. Ophthalmology 2001;108:272–8.
6. Topouzis F, Coleman AL, Choplin N, Bethlem MM, Hill R, Yu F, et al. Follow-up of the original cohort with the Ahmed glaucoma valve implant. Am J Ophthalmol 1999;128:198–204.
7. Kook MS, Yoon J, Kim J, Lee MS. Clinical results of Ahmed glaucoma valve implantation in refractory glaucoma with adjunctive mitomycin C. Ophthalmic Surg Lasers 2000;31:100–6.
8. Wilson MR, Mendis U, Paliwal A, Haynatzka V. Long-term follow-up of primary glaucoma surgery with Ahmed glaucoma valve implant versus trabeculectomy. Am J Ophthalmol 2003;136:464–70.
9. Gedde SJ, Herndon LW, Brandt JD, Budenz DL, Feuer WJ, Schiffman JC. Surgical complications in the Tube Versus Trabeculectomy Study during the first year of follow-up. Am J Ophthalmol 2007;143:23–31.
10. Bayer A, Önol M. Clinical outcomes of Ahmed glaucoma valve in anterior chamber versus ciliary sulcus. Eye (Lond) 2017;31:608–14.
11. Weiner A, Cohn AD, Balasubramaniam M, Weiner AJ. Glaucoma tube shunt implantation through the ciliary sulcus in pseudophakic eyes with high risk of corneal decompensation. J Glaucoma 2010;19:405–11.
12. Lee EK, Yun YJ, Lee JE, Yim JH, Kim CS. Changes in corneal endothelial cells after Ahmed glaucoma valve implantation: 2-year follow-up. Am J Ophthalmol 2009;148:361–7.
13. Eslami Y, Mohammadi M, Fakhraie G, Zarei R, Moghimi S. Ahmed glaucoma valve implantation with tube insertion through the ciliary sulcus in pseudophakic/aphakic eyes. J Glaucoma 2014;23:115–8.
14. Souza C, Tran DH, Loman J, Law SK, Coleman AL, Caprioli J. Long-term outcomes of Ahmed glaucoma valve implantation in refractory glaucomas. Am J Ophthalmol 2007;144:893–900.
15. Siegner SW, Netland PA, Urban RC Jr, Williams AS, Richards DW, Latina MA, et al. Clinical experience with the Baerveldt glaucoma drainage implant. Ophthalmology 1995;102:1298–307.
16. Ayyala RS, Zurakowski D, Smith JA, Monshizadeh R, Netland PA, Richards DW, et al. A clinical study of the Ahmed glaucoma valve implant in advancedglaucoma. Ophthalmology 1998;105:1968–76.
17. Harbick KH, Sidoti PA, Budenz DL, Venkatraman A, Bruther M, Grayson DK, et al. Outcomes of inferonasal Baerveldt glaucoma drainage implant surgery. J Glaucoma 2006;15:7–12.
18. Aung T, Seah SK. Glaucoma drainage implants in Asian eyes. Ophthalmology 1998;105:2117–22.
19. Rush R. Ciliary sulcus Ahmed Glaucoma Valve tube placement in neovascular glaucoma. Ophthalmic Surg Lasers Imaging 2009;40:489–92.
20. Tello C, Espana EM, Mora R, Dorairaj S, Liebmann JM, Ritch R. Baerveldt glaucoma implant insertion in the posterior chamber sulcus. Br J Ophthalmol 2007;91:739–42.
21. Rumelt S, Rehany U. Implantation of glaucoma drainage implant tube into the ciliary sulcus in patients with corneal transplants. Arch Ophthalmol 1998;116:685–7.