Turkish Journal of Medical Sciences

http://journals.tubitak.gov.tr/medical/

Research Article

Turk J Med Sci
(2017) 47: 883-890
© TÜBİTAK
doi:10.3906/sag-1604-46

Groin and thigh reconstructions with pedicled rectus abdominis myocutaneous flaps

Hakan UZUN[1,*], Ozan BİTİK[1], Yahya BALTU[2], Mehmet DADACI[3], Aycan Uğur KAYIKÇIOĞLU[1]

[1]Department of Plastic, Reconstructive, and Aesthetic Surgery, Faculty of Medicine, Hacettepe University, Ankara, Turkey
[2]Department of Plastic, Reconstructive, and Aesthetic Surgery, Ankara Oncology Hospital, Ankara, Turkey
[3]Department of Plastic, Reconstructive, and Aesthetic Surgery, Meram Faculty of Medicine, Necmettin Erbakan University, Konya, Turkey

Received: 11.04.2016 • **Accepted/Published Online:** 12.12.2016 • **Final Version:** 12.06.2017

Background/aim: Resection of tumors from the groin and thigh regions with safe margins often results in significant soft tissue defects, which preclude primary closure. This study presents a series of rectus abdominis myocutaneous flaps for irradiated thigh and groin wounds with the purpose of evaluating the efficacy and outcomes of these flaps in this population.

Materials and methods: From 2008 to 2015, all patients who underwent resection of thigh or groin region tumors and reconstruction with an inferiorly based rectus abdominis myocutaneous flap were retrospectively identified. Medical records of the patients were reviewed.

Results: A total of 27 patients, aged 20–67 years, were operated on for defects in the groin and upper thigh region. Nine patients underwent immediate reconstruction. The remaining 18 patients underwent late reconstruction. There was neither total flap loss nor partial flap loss. We chose to utilize 15 ipsilateral and 12 contralateral pedicles. The mean length of stay in hospital was 13.7 days.

Conclusion: A rectus abdominis myocutaneous flap can be successfully used in patients with groin and upper thigh defects due to its predictable and robust vascular supply, bulky muscle content, wide arc of rotation, and large skin island.

Key words: Groin, limb-sparing surgery, rectus abdominis flap, soft tissue reconstruction, thigh

1. Introduction

Soft tissue reconstruction is an inseparable part of limb-sparing surgery resulting from radical resections and irradiation (1). Resection of a tumor with safe oncologic margins often ends up with large defects, which cannot be closed primarily or are closed under high tension. Irradiation makes successful closure of these wounds even more difficult (1,2). Soft tissue defects after limb-sparing surgery in the thigh and groin region are distinct with regard to anatomy, complication rates, and reconstructive options (3). This area includes vital structures like femoral vessels and the femoral nerve. It has been reported that these wounds have a higher percentage of complications than other areas of the lower extremities, leading to a higher incidence of infection and dehiscence (4).

The inferiorly based rectus abdominis myocutaneous (RAM) flap provides well-vascularized, nonirradiated, bulky tissue from a healthy donor site (2). It can be used in several indications including but not limited to sacrectomy defects (5), lumbar and back defects, and amputation stumps (6). Modifications such as the oblique or extended RAM flap allow closure of more distal and contralateral wounds (7,8). This study aims to present a series of thigh and groin reconstructions with pedicled vertical and oblique RAM (VRAM and ORAM, respectively) flaps, to discuss their utility, and to demonstrate that the earlier involvement of a plastic surgery team decreases the complication rate.

2. Materials and methods

From 2008 to 2015, all patients who underwent resection of thigh or groin region tumors and reconstruction with an inferiorly based RAM pedicle flap were retrospectively identified. The medical records of patients were reviewed for demographics, tumor pathology and location, timing of the reconstruction, flap size and design, and length of stay in hospital. Patients were grouped into two categories according to the timing of the reconstruction. The patients who were operated on just after the tumor resection by orthopedic surgeons constituted the immediate reconstruction group and those who were operated on due to wound breakdown constituted the late reconstruction group.

* Correspondence: shakanuzuns@gmail.com

2.1. Operative technique

Generally, an ipsilateral flap was intended unless contraindicated because of abdominal surgical scars or injury of the deep inferior epigastric vessels (DIEVs). A VRAM flap was designed depending upon the dimension of the defect. Flap width was determined by the ability to close the donor site primarily. Regardless of the flap design, the skin island was incised and dissected above the external oblique muscle fascia and anterior rectus sheath until the lateral and medial perforators of the DIEVs were encountered (or until the periumbilical perforators were encountered while harvesting the ORAM flap). A minimum amount of muscle fascia was included within the flap. The rectus muscle was incised superiorly and then elevated off the posterior rectus sheath. DIEVs were found within the fat pad just lateral to the inferior part of the rectus muscle and dissected circumferentially to the origin at the external iliac system. In some of the patients, the muscle insertion was divided from the pubic crest and symphysis to increase the arc of rotation. Flaps were either tunneled subcutaneously or propelled and inset into the defect. The anterior rectus sheath was closed primarily and a layer of synthetic polypropylene mesh was used to reinforce the repair.

2.2. Statistical analysis

Statistical analysis of the data was performed by using SPSS 17 (SPSS Inc., Chicago, IL, USA). The length of stay in the hospital and complications were compared between immediate and late reconstruction groups by using a t-test. $P \leq 0.05$ was considered significant.

3. Results

3.1. Demographic findings

A total of 27 patients aged 20–67 (mean: 49.2) years were operated on for the defects in the groin and upper thigh region. Nine patients underwent immediate reconstruction. For the remaining 18 patients, late reconstruction was performed. In all of the patients for whom late reconstruction was done, the wound was originally managed by the referring service. Among them there were 4 patients who had unsuccessful local flap attempts.

3.2. Flap characteristics

We chose to utilize 17 ipsilateral (63%) (Figures 1 and 2) and 10 contralateral pedicles (37%) (Figures 3 and 4). Twenty-one VRAM flaps and 6 ORAM flaps (Figures 5 and 6) were used. There was neither partial nor total flap loss. Additional split-thickness skin grafting was necessary for 3 patients.

3.3. Hospitalization

The mean length of stay in the hospital following surgery for the immediate reconstruction group was significantly shorter than that of the late reconstruction group (11.3 days vs. 14.9 days, respectively; $P < 0.05$).

Figure 1a. Preoperative appearance of a defect of the right inguinal and upper thigh region.

Figure 1b. Early postoperative result following reconstruction with an ipsilateral pedicled VRAM flap and grafting.

3.4. Complications

One patient with late reconstruction died at the postoperative 6th hour due to massive myocardial infarction. We did not observe any wound healing complication at the donor site in either group. However, there was chronic purulent drainage and wound breakdown at the recipient site in five patients with late reconstruction. They were managed through the use of intravenous antibiotics with debridement and irrigation of the wound bed in the operating room. The resulting defects were left to secondary wound healing. No bedside suturing was attempted. In another patient with late reconstruction, hematoma formation was encountered. The wound was explored in the operating room. An arterial bleeding, originating from a side branch of the deep inferior

Figure 2a. Preoperative appearance of a defect of the left inguinal and upper thigh region.

Figure 2b. Early postoperative result following reconstruction with an ipsilateral pedicled VRAM flap.

Figure 2c. Postoperative 6th month appearance.

epigastric artery, was seen and hemostasis was achieved by clipping it. One patient with late reconstruction developed lymphedema (Figure 3). The late reconstruction group had significantly more complications than the immediate group ($P < 0.05$).

The characteristics of patients and list of complications are summarized in Tables 1–3.

4. Discussion

Radical resection of a tumor from the groin often ends in large defects that are difficult to be closed primarily or are closed under high tension. Presence of infected hardware, synthetic vessel grafts, and vital structures like femoral vessels make the closure more troublesome. Thus, these wounds have a higher percentage of complications than other areas of the lower extremities, leading to a higher incidence of infection and dehiscence (9). Large soft tissue defects after tumor resection or as consequence of wound healing difficulties in patients with malignant disease require rapid and safe coverage. Simple skin grafting is not sufficient to cover protect exposed bones, nerves, vessels, and hardware. Local flap options are not generally feasible due to previous incisions and the effects of radiotherapy. Although free flaps play an important role in the management of these defects in otherwise healthy patients, they may require longer operation durations and overburden patients in critical condition, such as those with progressive malignant disease. In these situations, sufficient soft tissue coverage needs to be achieved by simple and reliable techniques with moderate donor site morbidity (10).

After the first report of the successful transposition of a VRAM flap for abdominal wall reconstruction (11), it has become accepted as standard treatment in defect coverage of the trunk and the proximal thigh (5,6,10,12–14). We mostly preferred the pedicled VRAM flap, as it can be elevated and inset rapidly, has a wide arc of rotation, does not require a change in the patient's position, does not require dissection of irradiated vessels, and allows transfer of muscle with a large skin island (2,15). Its donor site can be easily closed primarily. Because the donor site is not in the lower extremities, extremity function, leg vasculature, and lymphatic drainage should not be affected. In addition, the VRAM flap can be used in a contralateral fashion if the ipsilateral epigastric vessels have been ligated.

Figure 3a. Preoperative appearance of a defect of the left inguinal and upper thigh region.

Figure 3b. Early postoperative result following reconstruction with a contralateral pedicled VRAM flap.

Figure 3c. Postoperative 1st year appearance with dramatic lower limb lymphedema.

Figure 4. Postoperative second week appearance of a patient reconstructed with a contralateral VRAM flap. Split-thickness skin grafts were needed to complete the closure.

In our study group, the complication rate and the mean length of hospital stay were significantly higher in the late reconstruction group than the immediate reconstruction group ($P < 0.05$). Infection at the recipient site constituted the main complication. In their large series, Parrett et al. (2) found a significant increase in complications — primarily infections — in delayed versus immediate flap reconstructed wounds. They concluded that these defects were likely still contaminated, thus resulting in the increased infection and dehiscence rates for delayed flap wounds. Therefore, we can conclude that the simultaneous reconstruction of groin and thigh defects together with the resection of the tumor result in fewer complications and quicker discharge from the hospital.

Various alternatives are present for the reconstruction of groin and proximal thigh defects, including sartorious, rectus femoris, tensor fascia lata, gracilis, and anterolateral

Figure 5a. The design of an extended ORAM flap.

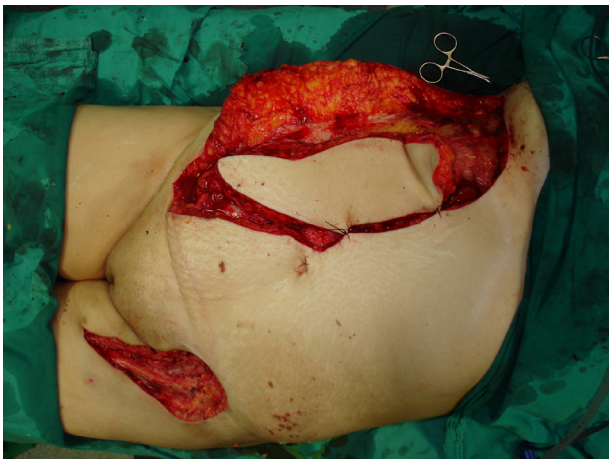

Figure 5b. Extended ORAM flap harvested; a subcutaneous tunnel was developed between the left inguinal defect and the flap donor site.

Figure 5c. Inset of the extended ORAM flap into the left inguinal defect.

Figure 6a. Preoperative appearance of the right inguinal region and the design of an ORAM flap.

Figure 6b. Early postoperative result following reconstruction with the ORAM flap.

Figure 6c. Postoperative 3rd month appearance.

Table 1. Characteristics of the patients with immediate reconstruction.

Age	Sex	Tumor	Location	Pedicle	Flap design	Flap size (cm)	Length of stay in hospital (days)
44	F	OS	Groin / thigh	Ipsilateral	VRAM	8 × 21	14
47	F	MMT	Thigh	Ipsilateral	VRAM	8 × 16	9
49	F	MMT	Groin / thigh	Ipsilateral	VRAM	8 × 16	13
62	F	MMT	Groin / thigh	Ipsilateral	VRAM	10 × 18	11
55	M	SCC	Groin	Ipsilateral	VRAM	8 × 16	9
52	F	MMT	Groin	Ipsilateral	ORAM	6 × 12	10
56	F	LS	Groin / thigh	Contralateral	ORAM	8 × 20	12
53	M	LS	Thigh	Contralateral	VRAM	6 × 14	13
49	M	MMT	Groin	Ipsilateral	ORAM	6 × 12	11

F: Female, M: male, OS: osteosarcoma, MMT: malignant mesenchymal tumor, SCC: squamous cell carcinoma, LS: liposarcoma, VRAM: vertical rectus abdominis myocutaneous, ORAM: oblique rectus abdominis myocutaneous.

Table 2. Characteristics of the patients with late reconstruction.

Age	Sex	Tumor	Location	Pedicle	Flap design	Flap size (cm)	Length of stay in hospital (days)
46	M	CS	Groin	Contralateral	VRAM	9 × 18	11
49	F	MMT	Thigh	Ipsilateral	VRAM	8 × 20	12
67	F	MMT	Groin / thigh	Ipsilateral	VRAM	9 × 22	None*
57	F	MMT	Groin	Contralateral	VRAM	8 × 14	22
44	M	DFSP	Groin	Ipsilateral	ORAM	6 × 12	11
62	F	MMT	Thigh	Contralateral	VRAM	8 × 16	13
48	M	MMT	Thigh	Ipsilateral	VRAM	8 × 16	21
55	M	DFSP	Groin / thigh	Contralateral	VRAM	10 × 18	13
52	M	MMT	Thigh	Ipsilateral	VRAM	8 × 16	16
53	M	MMT	Groin	Ipsilateral	ORAM	6 × 14	18
48	M	CS	Groin	Contralateral	VRAM	7 × 14	9
27	M	ES	Thigh	Contralateral	VRAM	8 × 18	13
58	M	LS	Groin / thigh	Contralateral	VRAM	6 × 16	18
60	F	MBC	Groin	Ipsilateral	VRAM	8 × 16	14
20	M	ES	Thigh	Ipsilateral	VRAM	8 × 16	16
46	F	MMT	Groin	Contralateral	VRAM	8 × 18	17
24	M	ES	Thigh	Ipsilateral	VRAM	6 × 14	15
46	F	MBC	Groin	Ipsilateral	ORAM	7 × 14	15

F: Female, M: male, CS: chondrosarcoma, MMT: malignant mesenchymal tumor, DFSP: dermatofibrosarcoma protuberance, LS: liposarcoma, ES: Ewing sarcoma, MBC: metastatic breast cancer, VRAM: vertical rectus abdominis myocutaneous, ORAM: oblique rectus abdominis myocutaneous.
*The patient died at the postoperative 6th hour.

thigh flaps (16–20). Although the use of the sartorious flap is associated with minimal donor morbidity, it has less tissue bulk and a limited arc of rotation due to its segmental type II blood supply. The bulkier rectus femoris muscle provides better coverage but may lead to weakness in knee extension (17,19). The tensor fascia

Table 3. Complications after RAM flap reconstructions.

Complication	Immediate reconstruction	Late reconstruction
Hernia	-	-
Flap loss	-	-
Donor site infection	-	-
Recipient site infection	-	5
Hematoma	-	1
Lymphedema	-	1
Mortality	-	1

lata flap is a valuable flap for the groin and has been used successfully for large defects because of its proximity to the region (21,22). Although it is associated with minimal functional morbidity, its donor site may need skin grafting. Additionally, its pedicle could be severed during tumor resection. The gracilis musculocutaneous flap is associated with minimal donor-site morbidity, but the distal part of the skin island that covers the defect has an unacceptably high rate of partial necrosis.

Groin defects could be reconstructed with thigh flaps. Nelson and Butler (23) demonstrated that thigh flaps had significantly higher rates of major complications, including major wound dehiscence and pelvic abscess, than VRAM flaps. Furthermore, thigh flap donor sites had higher rates of infection and took longer to heal than VRAM flap donor sites. However, LoGiudice et al. showed that anterolateral thigh flaps had a lower late postoperative complication rate and faster time to heal than the rectus abdominis flap (24). There was no statistical difference between these two flaps in the early postoperative period. All of the rectus abdominis-related late complications were hernias.

Musharafief et al. (25) used the rectus abdominis muscle flap for the reconstruction of the lower extremity in 40 patients because of chronic osteomyelitis, diabetic foot ulcers, soft tissue scars, or open fractures. They concluded that the high success rate in the control of infection reemphasized the fact that muscle flaps provide adequate control of bacterial inoculum through increased oxygen tension and increased phagocytic activity. Antibiotic delivery is improved and increased resistance to infection is achieved. In addition, the presence of valves in veins of the inferior epigastric system and intramuscular lymphatic bundles in the rectus muscle reduces the incidence of venous stasis, edema, and lymphedema in the dependent portion of these large flaps (26).

We encountered one case of late lymphedema in a patient who was reconstructed with a contralateral island VRAM flap. Daigeler et al. (10) found in their large series that the patients who did not receive island flaps but rather flaps with cutaneous pedicles developed less lymphedema. The idea behind this conclusion was that a cutaneous pedicle improves lymphatic drainage (27).

Modifications can be applied to the standard VRAM flaps in an attempt to mobilize larger well-vascularized soft tissue for coverage of large defects after debridement of complicated groin and thigh wounds. One of these modifications includes obliquely oriented RAM flaps based on periumbilical perforators (7). Potential advantages, including a long and thin skin paddle, increased reach and arc of rotation, ease of elevation and donor-site closure, and limited rectus fascia harvest, make the ORAM flap an attractive alternative to the VRAM flap for management of complex perineal and groin wounds (28). In our surgical practice, it took less time to harvest ORAM flaps when compared with VRAM flaps. In a recent study comparing VRAM and ORAM flaps, Combs et al. (8) showed that VRAM and ORAM flaps have unique strengths and disadvantages when used for complex perineal, pelvic, and groin reconstruction. They found no significant differences in donor-site or recipient-site complication rates.

The RAM flap can be successfully used in patients with groin and upper thigh defects because of its predictable and robust vascular supply, bulky muscle content, wide arc of rotation, and large skin island. Keeping in mind that a multidisciplinary approach is required for management of these patients, earlier involvement of the plastic surgery team decreases the complications.

References

1. Heller L, Kronowitz SJ. Lower extremity reconstruction. J Surg Oncol 2006; 94: 479-489.
2. Parrett BM, Winograd JM, Garfein ES, Lee WP, Hornicek FJ, Austen WG Jr. The vertical and extended rectus abdominis myocutaneous flap for irradiated thigh and groin defects. Plast Reconstr Surg 2008; 122: 171-177.
3. Bostwick J 3rd, Hill HL, Nahai F. Repairs in the lower abdomen, groin, or perineum with myocutaneous or omental flaps. Plast Reconstr Surg 1979; 63: 186-194.
4. Cannon CP, Ballo MT, Zagars GK, Mirza AN, Lin PP, Lewis VO, Yasko AW, Benjamin RS, Pisters PW. Complications of combined modality treatment of primary lower extremity soft-tissue sarcomas. Cancer 2006; 107: 2455-2461.
5. Akan M, Karaca M, Bilgiç İM, Aköz T. Sakrektomi defekti rekonstrüksiyonunda transabdominal vertikal rektus abdominis flebinin kullanımı: olgu sunumu. Turkish Journal of Plastic Surgery 2010; 18: 35-37 (in Turkish).

6. Duymaz A, Karabekmez FE, Keskin M. Using of pedicled rectus abdominis musculocutaneous flaps in the thigh and lumber defects. Ulus Travma Acil Cer 2014; 20: 443-451 (in Turkish with English abstract).

7. Lee MJ, Dumanian GA. The oblique rectus abdominis musculocutaneous flap: revisited clinical applications. Plast Reconstr Surg 2004; 114: 367-373.

8. Combs PD, Sousa JD, Louie O, Said HK, Neligan PC, Mathes DW. Comparison of vertical and oblique rectus abdominis myocutaneous flaps for pelvic, perineal, and groin reconstruction. Plast Reconstr Surg 2014; 134: 315-323.

9. Alkon JD, Smith A, Losee JE, Illig KA, Green RM, Serletti JM. Management of complex groin wounds: preferred use of the rectus femoris muscle flap. Plast Reconstr Surg 2005; 115: 776-785.

10. Daigeler A, Simidjiiska-Belyaeva M, Drucke D, Goertz O, Hirsch T, Soimaru C, Lehnhardt M, Steinau HU. The versatility of the pedicled vertical rectus abdominis myocutaneous flap in oncologic patients. Langenbecks Arch Surg 2011; 396: 1271-1279.

11. Mathes SJ, Bostwick J 3rd. A rectus abdominis myocutaneous flap to reconstruct abdominal wall defects. Br J Plast Surg 1977; 30: 282-283.

12. Steinau HU, Hebebrand D, Hussmann J. Reconstructive possibilities after extensive resection of malignant soft tissue tumors. Chirurg 1993; 64: 517-526.

13. Şenyuva C, Yücel A, Güzel Z, Okur İ, Bayrı O. Mikrovasküler cerrahide güvenli bir rekonstrüksiyon seçeneği; serbest alt transvers rektus abdominis kas-deri flebi (alt tram flepleri). Turkish Journal of Plastic Surgery 1995; 3 (in Turkish).

14. Bilkay U, Tokat C, Özek C, Çelik N, Gündoğan H, Gürler T, Alper M, Songür E. Vertikal rektus abdominis muskulokutan (VRAM) flebi ile kompleks yumuşak doku defektlerinin onarımı. Turkish Journal of Plastic Surgery 2002; 10 (in Turkish).

15. Murthy V, Gopinath KS. Reconstruction of groin defects following radical inguinal lymphadenectomy: an evidence based review. Indian J Surg Oncol 2012; 3: 130-138.

16. Aslim EJ, Rasheed MZ, Lin F, Ong YS, Tan BK. Use of the anterolateral thigh and vertical rectus abdominis musculocutaneous flaps as utility flaps in reconstructing large groin defects. Arch Plast Surg 2014; 41: 556-561.

17. Alkon JD, Smith A, Losee JE, Illig KA, Green RM, Serletti JM. Management of complex groin wounds: preferred use of the rectus femoris muscle flap. Plast Reconstr Surg 2005; 115: 776-783.

18. Koshima I, Soeda S, Ohno A. Combined tensor fasciae latae musculocutaneous flap and sartorius musculocutaneous flap for the repair of wide defects of the lower leg. Plast Reconstr Surg 1990; 86: 1198-1201.

19. Caulfield WH, Curtsinger L, Powell G, Pederson WC. Donor leg morbidity after pedicled rectus femoris muscle flap transfer for abdominal wall and pelvic reconstruction. Ann Plast Surg 1994; 32: 377-382.

20. Evriviades D, Raurell A, Perks AG. Pedicled anterolateral thigh flap for reconstruction after radical groin dissection. Urology 2007; 70: 996-999.

21. Hill HL, Hester R, Nahai F. Covering large groin defects with the tensor fascia lata musculocutaneous flap. Br J Plast Surg 1979; 32: 12-14.

22. Rifaat MA, Abdel Gawad WS. The use of tensor fascia lata pedicled flap in reconstructing full thickness abdominal wall defects and groin defects following tumor ablation. J Egypt Natl Canc Inst 2005; 17: 139-148.

23. Nelson RA, Butler CE. Surgical outcomes of VRAM versus thigh flaps for immediate reconstruction of pelvic and perineal cancer resection defects. Plast Reconstr Surg 2009; 123: 175-183.

24. LoGiudice JA, Haberman K, Sanger JR. The anterolateral thigh flap for groin and lower abdominal defects: a better alternative to the rectus abdominis flap. Plast Reconstr Surg 2014; 133: 162-168.

25. Musharafieh R, Macari G, Hayek S, Elhassan B, Atiyeh B. Rectus abdominis free-tissue transfer in lower extremity reconstruction: review of 40 cases. J Reconstr Microsurg 2000; 16: 341-345.

26. Khalil HH, El-Ghoneimy A, Farid Y, Ebeid W, Afifi A, Elaffandi A, Mahboub T. Modified vertical rectus abdominis musculocutaneous flap for limb salvage procedures in proximal lower limb musculoskeletal sarcomas. Sarcoma 2008; 2008: 781408.

27. Fansa H, Warnecke IC, Bruner S, Frerichs O. Surgical treatment of groin soft tissue defects. Chirurg 2006; 77: 447-452 (in German with English abstract).

28. Abbott DE, Halverson AL, Wayne JD, Kim JY, Talamonti MS, Dumanian GA. The oblique rectus abdominal myocutaneous flap for complex pelvic wound reconstruction. Dis Colon Rectum 2008; 51: 1237-1241.